Immediate Ambulation after a First Metatarsophalangeal Joint Fusion using a Locking Plate: Technique and case reports

by Robert M Greenhagen, DPM[1], Shelly A Wipf, DPM[1], Adam R Johnson, DPM[2], Patrick J Nelson, DPM[3], Nicholas J Bevilacqua, DPM[4]

The Foot and Ankle Online Journal 3 (4): 2

Purpose: *Arthrodesis of the first metatarsophalangeal joint (MTPJ) is a predictable procedure to relieve pain and dysfunction of the first MTPJ. Many fixation techniques have been described. The authors present two cases in which a locking plate was successfully used for first MTPJ fusion. The patients began immediate weight-bearing post-operatively without a delay in union, hardware failure, or malalignment.*
Methods: *A retrospective chart and radiographic review of a 53 year-old male and a 59 year-old female was performed. Serial radiograph was taken to assess fusion at the arthrodesis site.*
Procedures: *Cartilage was resected from the head of the first metatarsal and base of the proximal phalanx preserving the curvature of the joint. The joint was placed in the desired position and interfragmental compression was obtained using a cannulated 4.0-millimeter partially threaded screw from proximal medial to distal lateral with all threads crossed the fusion site. A locking plate was then placed on the dorsal aspect of the joint and secured with locking screws proximal and distal.*
Results: *The patients began ambulating immediately post-operatively with a post-operative shoe. Both patients had successful fusion by 8 weeks with good alignment and intact fixation. Patients returned to regular shoe gear once trabeculation was noted.*
Conclusion: *These 2 case reports suggest excellent results and immediate ambulation with compression screws and locking plates. This clinical report shows promise in regards to early ambulation using locking plate fixation technique and further studies are encouraged.*

Key words: Arthrodesis, first metatarsophalangeal joint, MTPJ fusion, locking plate.

Accepted: March, 2010 **Published:** April, 2010

Arthrodesis of the first metatarsophalangeal joint (MTPJ) is a predictable procedure to relieve pain and dysfunction of the first MTPJ.

The indications for this common procedure include hallux rigidus, rheumatoid arthritis, revision of failed bunion surgery, implant arthroplasty, and Keller procedures, and deformities secondary to neuromuscular disease such as cerebral palsy and poliomyelitis.[1] Fixation techniques vary from crossed Kirschner wires[1], intramedullary Steinman pins[2], intramedullary screws[3-5], crossed lag screws[6], external fixation[7], and plate fixation with interfragmentary screw.[2-8]

Address correspondence to: Robert M. Greenhagen, DPM, UPMC Podiatric Residency Program, Pittsburgh, PA.

[1] Podiatric Residents, UPMC Podiatric Residency Program, Pittsburgh, PA
[2] Podiatric Resident, Hennepin County Medical Center, Minneapolis, MN
[3] Podiatric Resident, Saint Vincent Charity Hospital, Cleveland, OH
[4]Associate Medical Director, Amputation Prevention Center, Valley Presbyterian Hospital, Los Angeles, CA

ISSN 1941-6806 doi: 10.3827/faoj.2010.0304.0002

Figure 1 Pre-operative radiographs show severe joint space narrowing and sclerotic subchondral changes. (A) Radiographs at seven weeks show full trabeculation and intact hardware. (B)

Protocols for post-operative ambulation have varied throughout the literature, and there have been numerous reports of early weight-bearing with favorable union rates, albeit most of these studies reported patients ambulating in a rigid post-op shoe or short leg walking cast that eliminated the propulsive phase of gait.[2,9-12] To our knowledge, there are currently no reported cases evaluating the use of locking plates for first MTPJ fusion. The purpose of this report is to examine results with immediate ambulation after first MTPJ with compression screws and locking plates.

Case Report 1

A 59 year-old female presented to the foot and ankle clinic with severe pain to the right first MTPJ. She had undergone an Austin bunionectomy previously, and now presented with severely limited and painful joint range of motion. Radiographs were consistent with asymmetric joint space narrowing and degenerative joint disease. (Fig. 1) The patient was informed of the risk, benefits and complications of both the procedure and the new post-operative protocol.

Figure 2 Pre-operative radiographs show severe hallux rigidus with diffuse joint space narrowing and flattening of the metatarsal head. (A) Postoperative week eight, osseous union is noted with no signs of hardware failure. (B)

Informed consent was obtained and the patient underwent a first MTPJ arthrodesis with a compression screw and a four-hole locking plate. Seven weeks after surgery, the patient presented for follow-up in normal footwear with pain free ambulation. Radiographs revealed trabeculation across the fusion site, with good alignment and intact fixation. (Fig. 2)

Case Report 2

A 53 year-old male presented with localized severe pain to his right first MTPJ. The patient had minimal range of motion and radiographs showed significant degeneration and non-uniform narrowing of the joint space. (Fig 2A) The patient exhausted conservative care and desired surgical management. The patient was informed of the risk, benefits and complications of both the procedure and the new post-operative protocol. Informed consent was obtained and the patient underwent a first MTPJ arthrodesis with a compression screw and a four-hole locking plate. (Fig. 2B)

Figure 3 A dorsal medial approach is made which allows reaming of the proximal phalanx and first metatarsal head.

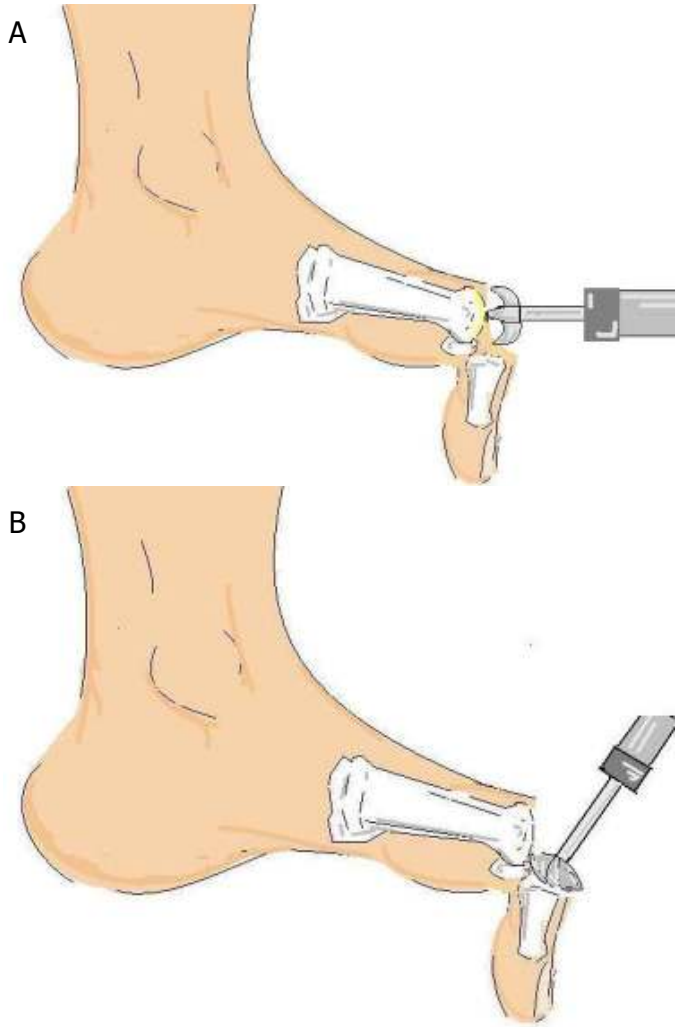

Figure 4 The cup portion of the reamer is used first to remove all cartilage from the metatarsal head. (A) The phalanx is reamed with the cone reamer. By performing the metatarsal head first, more room is made for cumbersome cone reamer. (B) (Illustration by Patrick Nelson, DPM©)

Post-operatively, the patient was placed in a surgical shoe and instructed to ambulate as tolerated. Eight weeks after surgery, the patient presented in normal shoe gear and pain free ambulation. Radiographs showed trabeculation, excellent alignment and intact fixation.

Technique

A dorsal medial incision was made and layered dissection was continued down to the level of the joint. (Fig. 3) Cartilage was resected from the head of the first metatarsal and base of the proximal phalanx preserving the curvature of the joint using a cup and cone reamer. (Fig. 4) The joint was placed in the desired position (slight dorsiflexion and abduction) and interfragmental compression was obtained using a 4.0-millimeter partially threaded cannulated screw. The screw was placed from proximal medial to distal lateral being sure that all threads crossed the joint. (Fig. 5) The alignment of the joint and position of the screw was directly visualized using intra-operative fluoroscopy. The locking plate was placed on the dorsal aspect of the joint and secured with locking screws proximal and distal. (Fig. 6) The wound is closed in layers and a dressing is applied.

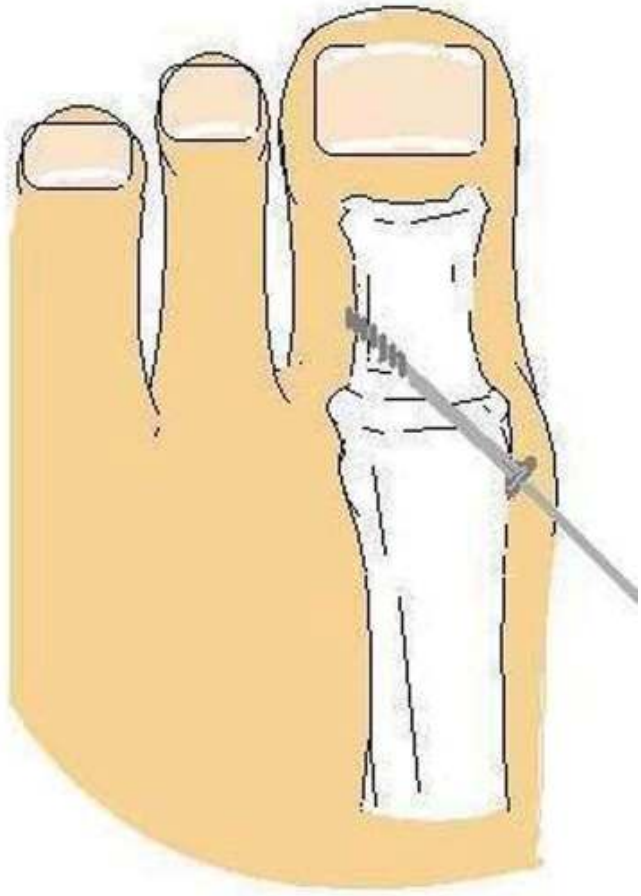

Figure 5 An interfragmentary screw can be placed from proximal medial to distal lateral. This provides both compression and fixation that does not interfere with the dorsal plate. We recommend the use of a cannulated screw for simplicity. (Illustration by Patrick Nelson, DPM©)

Patients are placed in a post-operative shoe and instructed to ambulate as tolerated. Patients are transitioned to normal footwear once clinical and radiographic signs of healing are appreciated.

Discussion

Many fixation techniques have been described for first MTPJ arthrodesis.[2-4,6-8,13] The ideal fixation technique for MTPJ arthrodesis should maintain stability and position of the fusion site while osseous union occurs.

Figure 6 Dorsal plating of the joint provides rigid fixation of the fusion site.

A review of the literature favors interfragmentary screw fixation as the strongest construct. Neufeld and colleagues compared memory compression staples, cannulated screws, and a five-hole, one-third tubular plate contoured to fit the arthrodesis site in 21 matched fresh-frozen cadaver specimens.[14]

Each specimen was loaded to failure in a cantilever fashion and an extensometer was used to measure gapping across the arthrodesis site, with failure defined as a 2-mm gap. They found that the crossed cannulated screws and the dorsal plate constructs failed at significantly higher loads than the two compression staples ($p<0.029$ and $p<0.002$, respectively).[14] The dorsal plate failed due to bending of the plate in 79% of specimens. While the crossed cannulated screws provided the greatest amount of rigidity, failure occurred when the screw fractured the metatarsal head at the screw-bone interface in all but one specimen.

Curtis and colleagues found interfragmentary screws to be superior to plate fixation due to bending of the plate.[15] They suggested that adding a screw or K wire placed obliquely to the axis of the MTPJ might improve stability. Politi, et al., used synthetic bone models to demonstrate that the most stable technique was an oblique interfragmentary lag screw with a dorsal plate.[16]

There are several problems with conventional plate application. The stability of a plate relies on compression between the plate and the cortical bone, potentially disrupting the periosteal blood supply and inducing porosity of the bone.[17] To apply a screw to a conventional plate, it must be tightened with an axial traction of 1000-2000 Newtons (N), which produces up to 2400 N of friction in a 4-hole plate (co-efficient of friction between metal and bone = 0.4).[18] In addition, plate application to the first MTPJ is fraught with biomechanical disadvantages. The AO (Arbeitsgemeinschaft für Osteosynthesefragen) group recommends that a plate be positioned on the tension side of a bone to create dynamic compression in accordance with the tension band principle.[1] In a loaded first MTPJ, the tension side is the convex plantar surface of the joint. Due to the position of the sesamoids, soft tissue structures, and potential complications of plantar incisions, the ideal placement of the plate on the tension side of the joint is not feasible, and the plate must be placed on the concave dorsal or compression side of the joint. Since the plate thus applied cannot supply tension band fixation, it will instead serve a neutralization function to protect the lag screw from shearing, bending, and torsional forces.

The locking plate design overcomes several of the disadvantages of conventional plate fixation and when combined with the use of an interfragmentary lag screw for compression, may provide a construct sufficiently stable to allow early weight-bearing and successful arthrodesis. The screw holes of the locking plate have threads that match the conically threaded undersurface of the screw heads, locking the screw head to the plate and negating the need for the plate to be compressed against the bone, thus minimizing the potential for disruption of the periosteal blood supply.[18,20] The locking mechanism between the screw and the plate prevents toggle and screw back out which may result from micromotion of up to 90% body weight that could be transferred onto the first MTPJ during gait.[21] In addition, the locking properties of the plate and screws render failure impossible unless there is simultaneous pullout of all the screws.[22] Gallentine and colleagues reported the use of locking plate fixation of proximal metatarsal chevron osteotomies, finding that the locking plate was successful in maintaining alignment and position of the first ray in patients who were allowed to bear weight on their heel immediately postoperatively.[23] In a study of synthetic calcaneal fracture models, the stability of plates with locking screws and conventional plates without locking screws was compared.[24] It was shown that the locking plates provided greater stability than the conventional plates with high cyclic loading simulating full weight-bearing.

In an in-vitro study of first metatarsocuneiform arthrodesis, Cohen, et al., argued that one of the shortcomings of the locking plate is that while it is rigid at the screw to plate to bone interface, it provides no compression at the arthrodesis site.[25] The authors of the current case report assert that the addition of the interfragmentary screw at the fusion site allows for compression, obviating the need for compression by the biomechanically disadvantaged plate. In this way, the plate functions to neutralize weight-bearing forces, while avoiding the aforementioned failure at the screw-bone interface by the intrinsic properties of the locking mechanism.

Allowing immediate ambulation after first MTPJ arthrodesis decreases the morbidity of the procedure by reducing disuse atrophy and osteopenia, the risk of deep thrombosis/pulmonary embolism, and inconvenience to the patient. When fixated with adequate internal fixation, the first MTPJ arthrodesis is a stable construct which allows the patient to ambulate immediately postoperatively. This notion has received support throughout the literature. In his early description of first MTPJ fusion in 1952, McKeever recommended weight-bearing in a cut-out shoe at the third or fourth post-operative day, though he noted that he cautioned the patient *"very strongly"* against placing full weight on the toe for six weeks.[5] Immediate ambulation in a wooden-soled postoperative shoe or short walking boot is the standard of care reported in a major orthopaedic text.[26]

In a retrospective review of 47 first MTPJ arthrodeses, Dayton reported a 100% fusion rate when allowing immediate post-operative ambulation with a standard surgical shoe, restricting weight to the heel or lateral aspect of the foot.[9] A randomized, prospective study of 61 cases found a 97% fusion rate for the early weightbearing group and a 93% fusion rate for the delayed weightbearing group, suggesting no difference in radiographic union or clinical outcome between patients who began ambulating two to four days post-operatively and those who remained non-weightbearing for four weeks.[12] Most authors recommend the use of a post-operative shoe or a CAM boot to eliminate the propulsive phase of gait, thus decreasing the chance for fixation failure. Young and colleagues compared three types of post-operative boots with a fiberglass cast in a cadaver model using strain gauges in the first MTPJ joint and simulated weightbearing.[27] They found that the removable cast boots provided the same, and in one type, even more reduction of force across the arthrodesis site than a traditional fiberglass cast.

The exact amount of force that a first MTPJ arthrodesis site can tolerate before failing is still unknown. The authors recognize that in certain situations, the force to failure may be reduced, such as revision arthrodeses utilizing bone grafts, cases in which less than optimal fixation is achieved, or large patient habitus. In such cases, an early weightbearing protocol may not be appropriate.

Further limitations of this case report include the small number of cases, selection and evaluation bias. The small number is due to the fact that all patients were directly seen by the junior authors. The senior author may have had other patient's that would have satisfied the selection criteria, but were not included. This may have lead to an unintended selection bias. All patients and radiographs were evaluated by the senior author. Evaluation bias may have also occurred. The patients' digital radiographs are included to address this concern. While the authors recognize these limitations, we do not advocate a change in the standard of care based solely on limited case studies alone and further studies are needed.

Conclusion

The authors have presented 2 cases of early ambulation following first MTPJ arthrodesis with a successful result using a locking plate with an interfragmentary screw. This clinical report shows promise for first MTPJ with regard to early and immediate ambulation following first MTPJ fusions.

References

1. Yu GV, Shook, JE. Arthrodesis of the first metatarsophalangeal joint. Current recommendations. JAPMA 1994 84(6): 66-80.
2. Smith RW, Joanis TL, Maxwell PD. Great toe metatarsophalangeal joint arthrodesis: a user-friendly technique. Foot Ankle 1992 13(7): 367-77.
3. Hansen ST. *Functional reconstruction of the foot and ankle*. 2000, Philadelphia: Lippincott Williams & Wilkins. xviii, 525
4. Castro MD, Klaue K. Technique tip: Revisiting an alternative method of fixation for first MTP joint arthrodesis. Foot Ankle Int 2001 22(8): 687-688.
5. McKeever DC. Arthrodesis of the first metatarsophalangeal joint for hallux valgus, hallux rigidus, and metatarsus primus varus. JBJS 1952 34A(1): 129-134.
6. Turan I, Lindgren U. Compression-screw arthrodesis of the first metatarsophalangeal joint of the foot. Clin Orthop Rel Res 987 (221): 292-295.
7. Harrison MHM, Harvey FJ. Arthrodesis of the first metatarsophalangeal joint for hallux valgus and ridigus. JBJS 1963 45A (3): 471-480.

8. Goucher NR, Coughlin MJ. Hallux metatarsophalangeal joint arthrodesis using dome-shaped reamers and dorsal plate fixation: A prospective study. Foot Ankle Int 2006 27(11): 869-876.
9. Dayton P, McCall A. Early weightbearing after first Metatarsophalangeal joint arthrodesis: a retrospective observational case analysis. J Foot Ankle Surg 2004 43(3): 156-159.
10. Sage RA, Lam AT, Taylor DT. Retrospective analysis of first metatarsal phalangeal arthrodesis. J Foot Ankle Surg 1997 36(6): 425-429 (discussion 467).
11. Flavin R, Stephens MM. Arthrodesis of the first metatarsophalangeal joint using a dorsal titanium contoured plate. Foot Ankle Int 2004 25(11): 783-787.
12. Lampe HIH, Fontijne P, van Linge B. Weight bearing after arthrodesis of the first metatarsophalangeal joint. A randomized study of 61 cases. Acta Orthop Scand, 1991 62(6): 544-555.
13. Coughlin MJ, Mann RA. Arthrodesis of the first metatarsophalangeal joint as salvage for the failed Keller procedure. JBJS 1987 69A(1): 68-75.
14. Neufeld SK, Parks BG, Naseef GS, Melamed EA, Schon LC. Arthrodesis of the first metatarsophalangeal joint: a biomechanical study comparing memory compression staples, cannulated screws, and a dorsal plate. Foot Ankle Int 2002 23(2): 97-101.
15. Curtis MJ, Myerson M, Jinnah RH, Cox QG, Alexander I. Arthrodesis of the first metatarsophalangeal joint: a biomechanical study of internal fixation techniques. Foot Ankle, 1993 14(7): 395-399.
16. Politi J, John H, Njus G, Bennett GL, Kay DB. First metatarsal-phalangeal joint arthrodesis: A biomechanical assessment of stability. Foot Ankle Int 2003 24(4): 332-337.
17. Perren SM, Cordey J, Rahn BA, Goutier E, Schneider E. Early temporary porosis of bone induced by internal fixation implants. A reaction to necrosis, not to stress protection? Clin Orthop Rel Res 1988 (232): 139-151.
18. Perren SM. Evolution of the internal fixation of long bone fractures. The scientific basis of biological internal fixation: choosing a new balance between stability and biology. JBJS 2002 84B (8): 1093-1110.
19. Müller ME, Allgoewer M, Schneider R, Willenegger H. *Manual of internal fixation : techniques recommended by the AO-ASIF Group*. 3rd Ed. 1991, Berlin ; New York: Springer-Verlag. xxviii, 750.
20. Rüedi TP, Murphy WM. *AO principles of fracture management*. 2000, Stuttgart ; New York; Davos Platz, [Switzerland]: Thieme; AO Pub. 864.
21. Wyss UP, McBride I, Murphy L, Cooke TD, Olney SJ. Joint reaction forces at the first MTP joint in a normal elderly population. J Biomech 1990 23(10): 977-984.
22. Kim T, Ayturk UM, Haskell A, Miclau T, Puttlitz CM. Fixation of osteoporotic distal fibula fractures: A biomechanical comparison of locking versus conventional plates. J Foot Ankle Surg 2007 46(1): 2-6.
23. Gallentine JW, Deorio JK, Deorio MJ. *B*union surgery using locking-plate fixation of proximal metatarsal chevron osteotomies. Foot Ankle Int 2007 28(3): 361-368.
24. Richter M, Gosling T, Zech S, Allami M, Geerling J, Droste P, Krettek C. A comparison of plates with and without locking screws in a calcaneal fracture model. Foot Ankle Int 2005 26(4): 309-319.
25. Cohen DA, Parks BG, Schon LC. Screw fixation compared to H-locking plate fixation for first metatarsocuneiform arthrodesis: a biomechanical study. Foot Ankle Int 2005 26(11): 984-989.
26. Coughlin MJ, Mann RA, Saltzman CL. *Surgery of the Foot and Ankle*. 8th Edition. 2007, Philadelphia: Mosby.
27. Young D, Stone NC, Molgaard J, Duford D. A biomechanical study in cadavers of cast boots used in the early postoperative period after first metatarsophalangeal joint arthrodesis. Can J Surg 2003 46(3): 183-186.