Open Access Publication

Congenital Bilateral First Brachymetatarsia: A Case Report and Review of Available Conservative and Surgical Treatment Options

by Mark J. Mendeszoon, DPM, FACFAS, FACFAOM [1], Yelena L. Kaplan, DPM [2], Robert S Crockett, DPM [3], Natalie Cunningham, DPM [4]

The Foot and Ankle Online Journal 2 (9): 1

Synonyms of first metatarsal brachymetatarsia include metatarsus primus atavicus, metatarsus primus brevis, metatarsus primus brevis varus syndrome, pied ancestral (French), pied de Neanderthal (French), short first metatarsal syndrome and Morton's syndrome (Dudley Joy Morton). Brachymetatarsia is a condition in which the metatarsal physis closes prematurely yielding a pathologically shortened metatarsal length. The podiatric and orthopedic literature mostly agree that the most common metatarsals to be affected are the fourth and third, although any of the five metatarsals can be affected. The etiology of this condition can be genetic or idiopathic, with strong female to male predilection. Presentation of first brachymetatarsia is far less common than that of third or fourth metatarsals. Management of this condition can present as a challenge to the foot and ankle surgeon. This case report will review the present conservative and surgical treatment options.

Key Words: Brachymetatarsia, Morton's syndrome, Hallux varus, metatarsus primus atavicus, metatarsus primus brevis, metatarsus primus brevis varus syndrome, short first metatarsal syndrome.

Accepted: July, 2009 **Published:** September, 2009

Brachymetatarsia of the first metatarsal is also known as "*Morton's syndrome*".[1] Tachdjian reported that first metatarsal is the most commonly affected metatarsal, although the incidence was found to be 1 in 10,000, whereas a majority of other podiatric and orthopaedic authors claim the fourth brachymetatarsia to be the most common.[2] The largest series of studies, which are from Japan, report the incidence of Morton's syndrome to be somewhere between 1 in 1820-4586 (0.022%-0.05%), and bilateral congenital brachymetatarsia is noted to be 72 %.[3,4]

Address correspondence to: Robert Crockett, DPM, Neshoba Foot and Ankle Clinic, 1004 Holland Ave. Philadelphia, MS
Email: drrcrockett@gmail.com.

[1] Precision Orthopaedic Specialties, 150 Seventh Avenue, Suite 200 Chardon, OH 44106
[2,3,4] Louis Stokes Veterans Affairs Medical Center, Podiatric Primary Care & Surgery, 10701 East blvd Cleveland, OH 44106.

The etiology of brachymetatarsia can be associated with *idiopathic congenital conditions* and *acquired disorders*. Idiopathic congenital conditions can include such conditions as hereditary early epiphyseal plate closure, associated congenital disorders such as Down's, Turner's, Larsen's, Albright's syndromes, pseudohypoparathyroidism, poliomyelitis, dystrophic dysplasia, pseudohyperparathyroidism,, multiple epiphyseal dysplasia and myositis ossificans. Acquired disorders can include trauma, neurotrophic disorder, radiation exposure, surgical resection of metatarsal head, infection, or osteochondrosis.[5] There is a strong female to male predisposition in the majority of the podiatric and orthopedic literature. The average ratio is 25:1[3,6], and the majority of the population studied is between the ages of 5 and 14 years of age.[7] .

ISSN 1941-6806 doi: 10.3827/faoj.2009.0209.0001

Figure 1 Dorsal view of bilateral feet with short halluces.

Anatomy

The first metatarsal secondary ossification center is located at the lateral aspect of the metatarsal base. In 1971, Lelievre[8] stated that the order from longest to the shortest metatarsal should be 1 = 2>3>4>5. Harris and Beath[9] studied 7167 military recruits and found that metatarsals 1>2 in 40 %, 1=2 in 22 %, 1 <2 in 38 %. According to Schmizzi and Brage[3] "*the exact diagnosis of brachymetatarsia can be made when one metatarsal is 5mm or more proximal to the parabolic arc of the metatarsal heads.*"[6,10]

Mechanics

Because of its location in the medial longitudinal arch the first ray plays an integral role in providing stability and maintaining structural integrity during weight bearing activities.[18] In fact, the base of the first metatarsal is the site for insertion of extrinsic muscles that are vital for medial column stability.

The peroneus longus, anterior tibialis and posterior tibialis muscles all provide significant mechanical stabilizing forces during the toe off (propulsion) phase of gait. When the structural component of the medial longitudinal arch is compromised, abnormal function of the soft tissue is to be expected.

Pain is the most common symptom and is caused by a variety of etiologies such as:

1. Pain caused by stretching of the deep transverse intermetatarsal ligament.
2. A short metatarsal and associated proximal phalanx position between adjoining metatarsal heads.
3. Cock-up toe deformity[3], claw toe[11], and painful digital callus due to dorsal displacement of short metatarsal, associated proximal phalanx and correlating shoe pressure/irritation.
4. Transfer metatarsalgia [12] and transfer lesions.
5. Contractures of extensor/flexor tendons, capsule and skin can be seen with chronic deformities.

Case Report

A nine year-old, Amish female presented to the outpatient clinic, accompanied by her mother. The mother related the child's chief complaint as generalized soreness and pain in both feet and legs with the right foot being more painful than the left. The mother also explained that her daughter had difficulty ambulating and standing on her feet in the morning. While obtaining the history, both the patient and mother denied any history of injury or trauma to child's feet or legs. The child was enrolled into an Amish school full time and during the warm months of the year did not wear shoes. The mother denied having any problems during pregnancy with this child or any complications during the delivery. She also related that her daughter went through normal developmental stages, did not have any medical problems or allergies and did not take any medication. The family history revealed that the mother has a heart murmur and father had a stroke. All other family members are free of medical problems. Upon the review of systems, no remarkable findings were noted.

Figure 2 Plantar view of foot with short hallux.

On physical examination the patient's neurovascular and the dermatological examinations of the lower extremities were completely within normal limits. We did not observe any transfer lesions or callosities. However, on musculoskeletal examination it was noted that both halluces were very short when compared to the adjacent digits. (Figs. 1 and 2) In addition, the child had pain at the insertion of Achilles tendon bilaterally and she was unable to dorsiflex her foot at the ankle joint beyond 90 degrees with the knee flexed and knee extended.

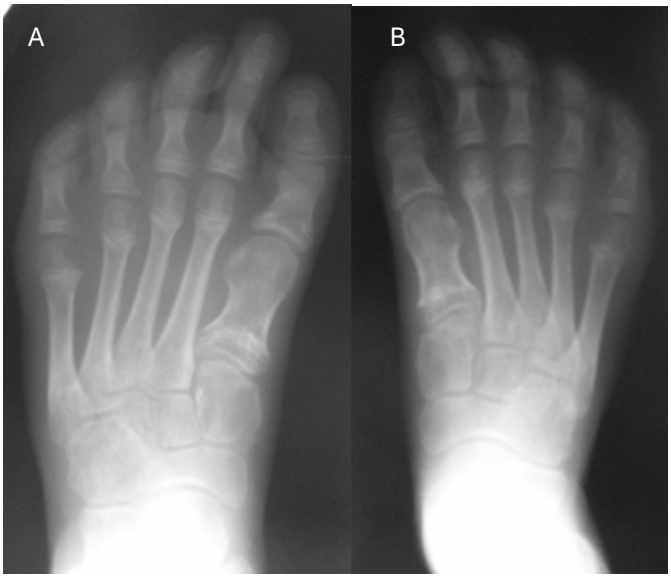

Figures 3 Anteroposterior (AP) radiograph of left (A) and right (B) foot with first brachymetatarsia.

On weight bearing examination, the child was unable to get the heel to the ground. The patient propelled on her forefeet during gait and the heels were in a varus alignment during the resting calcaneal stance position.

On evaluation of anteroposterior (AP) and lateral plain radiographs, a short first metatarsal with closed physis in both feet was observed. (Figs. 3 and 4) The left first metatarsal was noted to be shorter than the second metatarsal by 24 mm, and right first metatarsal was shorter than the second metatarsal by 20 mm. These findings were consistent with the definition of brachymetatarsia.

In addition, several other biomechanical factors were seen on radiograph. There is observed metatarsus adductus and decreased talo-calcaneal angles bilaterally, although the right is more pronounced than the left. This was combined with and possibly due to an uncompensated ankle equinus or talipes equinovarus.

Figures 4 The Lateral radiograph of the right (A) and left (B) foot with first brachymetatarsia.

The findings were discussed with the mother and the patient in detail. The patient was advised to initially be placed in custom orthotic device to evenly distribute plantar load and support the medial longitudinal arch. If the condition remained symptomatic after initial orthotic therapy, surgical correction involving distraction callotasis would be indicated upon near closure of adjacent metatarsals physes.

Discussion

For this young patient with symptomatic pathology, and the presence of biomechanical abnormalities contributing to the pain, conservative therapy is initially recommended. The orthotic therapy would allow the necessary correction for the uncompensated ankle equinus. Three months following our patient's initial consultation and orthotic therapy, the patient was doing well and not complaining of pain.

Taking into consideration this child's ethnic background, after cold winter months, the patient will return to barefoot activities, as stated by the patient and her mother. If our patient begins to experience pain and discomfort after discarding orthotic therapy, surgical correction will be indicated. Indication for treatment is usually related to pain, prevention of progressive deformity or cosmesis. There are a variety of treatments available for conservative treatment and surgical correction of first brachymetatarsia:

1. Orthotic devices, metatarsal pads, wide toe-box shoe gear.
2. Metatarsal heads 2-4 resection.
3. Proximal ostectomy of metatarsals 2-4, followed by (Teflon prosthesis) implant arthroplasty in first metatarsal.[13]
4. Chiappara[19] procedure: First proximal phalanx shortening, combined with shortening of proximal aspect of metatarsals 2, 3, 4 and lengthening medial cuneiform allowing hallucal interphalangeal (IPJ) to compensate for first metatarsophalangeal (MTP) joint.[13]

Surgical Lengthening procedures

1. One stage: distraction and bone graft.
2. Two stage: osteotomy and gradual distraction, followed by bone grafting.
3. Skirving and Newman procedure[20] = "*callotasis*": osteotomy and gradual lengthening of first metatarsal with external mini external fixator, without bone graft utilization.[13,14]
4. Metatarsal slide lengthening procedure.

The one stage surgical approach is best for lengthening metatarsals up to 15 mm. Bone grafting can be wth allograft (such as tricortical iliac crest) or autograft (such as calcaneal or tibial strut).[3,6] If a greater than 15 mm lengthening is desired or indicated, recommendation is to perform distraction callotasis with a mini external fixator. Begin distraction approximately 1 week after surgery, and distract 0.5 mm to 1 mm per day. Keep the patient completely non-weight bearing for 8 - 12 weeks. Once the desired length is achieved, stop the daily distraction. As weight bearing status is progressed, the mini external fixator is kept in place until radiograph evidence shows bone consolidation.

With any lengthening procedure, the patient can experience complications, especially when the total lengthening is greater than 40 % of original length.[3] With excessive lengthening, there is possible risk of neurovascular compromise, vasospasm and toe gangrene, unless pre-surgical soft tissue releases, stress-relaxation techniques, and keeping the total increased length to less than 15 mm are employed.[3] Other complications can include stiff metatarsophalangeal or MTP joint, subluxation of the MTP joint, nonunion of the distraction site, ray angulation deformity, prolonged time to achieve osseous union and pin track infection.[3,15]

Considering the child in our case report will need to have the first metatarsal lengthened by greater than 15 mm, a two-stage approach or distraction callotasis seems to be the most appropriate procedures. Choi, et al., performed callotasis on 9 patients with average length gained 17.6 mm (15-23 mm), and the average time for "*solid bony union*" being 2.6 months (1.7 - 3.4 months).[16] Steedman and Peterson performed gradual first metatarsal distraction with the use of mini-external fixators (5/6 mini-Hoffman, 1/6 Orthofix), followed by fibular bone graft placement after gaining the desired lengthening. The average amount of lengthening was 10.3 mm (6 mm - 20 mm), with an average healing time of 3.5 months (1.9 months - 6.1 months). According to Steedman and Peterson, either the two-stage approach or the callotasis are acceptable surgical choices for correction of first metatarsal brachymetatarsia versus "*procedures that shorten other metatarsals and destroy joints.*"[13] Other factors to consider: bone grafting versus callotasis? When performing callus distraction with bone grafting, the surgeon should consider allograft versus autograft, graft incorporation, soft tissue adaptation (neurovascular damage) and status of adjacent metatarsal physes prior to the procedure. Timing of the surgical procedure should be aimed at "*near closure of adjacent metatarsal physes*"[17], thus assuring static relative correction. In addition, soft tissue stretching is recommended prior to the procedure.

Conclusion

Brachymetatarsia is a condition that has been described since ancient times, but the options for surgical correction did not become available until 1969, when McGlamry and Cooper began using a cylindrical autogenous calcaneal bone graft to lengthen the fourth metatarsal.[6] Brachymetatarsia is a relatively rare condition which most often affects the fourth metatarsal. We have presented a case of a nine year old female with bilateral short first metatarsals. Considering the patient's age, length of deformities, the presence of uncompensated ankle equinus and metatarsus adductus, we have allowed this patient the opportunity for conservative management first. However, it is more than likely; a surgical correction of sorts will need to be performed to address this pathology. Many surgical options are available for correction of brachymetatarsia, but as with any surgery, the surgeon needs to be in tune with patient's expectations. This relates to cosmesis versus pain relief, choosing the best surgical procedure based on digital position, amount of lengthening necessary and bone graft (if necessary). It is ideal to consider a reasonable expectation for post-operative healing, possible complications and outcome.

References

1. http://www.whonamedit.com/synd.cfm/270 Date of access is required.
2. Tachdjian MO: "Disorders of the foot" in Tachdjian's *Pediatric Orthopaedics. E*d by JA Herring JA, WB Saunders, Philadelphia, 1990.
3. Schimizzi A, Brage M: Brachymetatarsia. Foot Ankle Clin N Am 9: 555 – 570, 2004.
4. Sagiura Y, Nakazawa O: Bone age: Roentgen diagnosis of skeletal development. Tokyo: Chugailgaku, 1968.
5. Munuera Martínez PV, Lafuente Sotillos G, Domínguez Maldonado G, Salcini Macías JL, Martínez Camuña L: Morphofunctional study of Brachymetatarsia of the fourth metatarsal. J Am Podiatr Med Assoc 94: 347 – 352, 2004.
6. Bartolomei FJ: Surgical correction of Brachymetatarsia. J Am Podiatr Med Assoc 80 (2): 76 – 82, 1990.
7. Goforth WP, Overbeek TD: Brachymetatarsia of the third and fourth metatarsals. J Am Podiatr Med Assoc 91: 373 – 378, 2001.
8. Lelievre J: Pathologie du pied [Pathology of the Foot]. Paris: Masson, 1971 (in French).

9. Harris RI, Beath T: The short first metatarsal: its incidence and clinical significance. J Bone Joint Surg 31A: 553 – 565, 1949.
10. Kim HT, Lee SH, Yoo CI, Kang JH, Suh JT: The management of brachymetatarsia. J Bone Joint Surg 85B: 683 – 690, 2003.
11. Magnan B, Bragantini A, Regis D, Bartolozzi P: Metatarsal lengthening by callotasis during the growth phase. J Bone Joint Surg Br 77B (4): 602 – 607, 1995.
12. Alter SA, Feinman B, Rosen RG: Chevron bone graft procedure for the correction of brachymetatarsia. J Foot Ankle Surg 34 (22): 200 – 205, 1995.
13. Steedman JT, Peterson HA: Brachymetatarsia of the first metatarsal treated by surgical lengthening. J Pediatr Orthop 12 (6): 780 – 785, 1992.
14. Ferrández L, Yubero J, Usabiaga J, Ramos L: Congenital brachymetatarsia: three cases. Foot Ankle 14 (9): 529 – 533, 1993.
15. Song HR, Oh CW, Kyung HS, Kim SJ, Guille JT, Lee SM, Kim PT: Fourth brachymetatarsia treated with distraction osteogenesis. Foot Ankle lnt 24 (9): 706 – 711, 2003.
16. Choi IH, Chung MS, Baek GH, Cho TJ, Chung CY: Metatarsal lengthening in congenital brachymetatarsia: One-stage lengthening versus lengthening by callotasis. J Pediatr Orthop 19 (5): 660 – 664, 1999.
17. Solomon MG, Blacklidge DK: Brachymetatarsia: Case report and surgical considerations. J Am Podiatr Med Assoc 8: 685 – 689,1995.
18. Glasoe WM, Yack HJ, Saltzman CL: Anatomy and biomechanics of the first ray. Phys Ther 79: 854 – 859, 1999.
19. Chiappara P: Utilisation de la dure-mére dans la chirurgie de l'avant-pied rhumatoide. Mèd Chir Pied **7**, 197 – 198, 1991.
20. Skirving AP, Newman JH: Elongation of the first metatarsal. J Pediatr Orthop 3 508 – 510, 1983.