

Protected Weight Bearing During Treatment of Acute Charcot Neuroarthropathy: A case series

by Jeremy J. Cook, DPM, MPH, CPH¹✉, Emily A. Cook, DPM, MPH, CPH²✉

The Foot and Ankle Online Journal 4 (7): 1

Standard of care in the treatment of acute Eichenholtz stage I Charcot neuroarthropathy includes complete non-weight bearing immobilized with total contact casting. This small case series of three patients focuses on patients with acute phase midfoot Charcot neuroarthropathy treated with non-casting immobilization therapy. All patients were male with a mean age of 48.7 (range 46-53) years. Patients were instructed to assume complete non-weight bearing during treatment. Due to financial restrictions, all patients reported fully weight bearing in the non-removable immobilization boot because of work related obligations. Immobilization therapy lasted a mean duration of 90.3 days (range 76 – 133 days) and was discontinued once there was clinical resolution of inflammation and osseous stability. Serial radiographs revealed absence of deformity progression and eventual consolidation in all cases. All patients remained ulcer and callus free during immobilization therapy, without progression of a rocker-bottom deformity, while fully weight bearing and maintaining full-time manual labor employment. This preliminary case series adds to the evidence base that it may be possible to allow protected weight bearing during acute phase Charcot neuroarthropathy with adequate immobilization of the foot at all times.

Key words: Diabetes, Charcot neuroarthropathy, Foot Deformity, Casting, Foot fractures, Diabetic Foot.

Accepted: June, 2011

Published: July, 2011

This is an Open Access article distributed under the terms of the Creative Commons Attribution License. It permits unrestricted use, distribution, and reproduction in any medium, provided the original work is properly cited. ©The Foot and Ankle Online Journal (www.faoj.org), 2011 All rights reserved.

Charcot neuroarthropathy is an increasingly common clinical entity encountered by foot and ankle professionals. In the early decades of the last century syphilis was the most commonly associated etiology. That has changed with the advent of insulin and the resulting extended survival of patients suffering from diabetes mellitus.

Delay in diagnosis and patient non-compliance can result in severe destruction of the foot and ankle with permanent disability from ulceration, infection, and eventual amputation.¹⁻¹⁴

The standard of care for treatment of Eichenholtz stage 1¹⁵ Charcot neuroarthropathy has been immobilization in a total contact cast and complete non-weight bearing.¹⁶⁻²⁰ The period of non-weight bearing immobilization should last until erythema, edema, and warmth subside and the foot becomes stable and consolidated enough to prevent anatomic destruction while ambulating. This process has been reported to last anywhere from a few months to over two years.²⁰⁻²⁶

Address correspondence to: Harvard Medical School, Beth Israel Deaconess Medical Center, Boston, MA.
Email: jeremycook@post.harvard.edu

^{1,2} Clinical Instructors in Surgery at Harvard Medical School, Division of Podiatric Surgery, Department of Surgery, 185 Pilgrim Road, PB Span 3, Beth Israel Deaconess Medical Center, Boston, MA. 617-632-7098

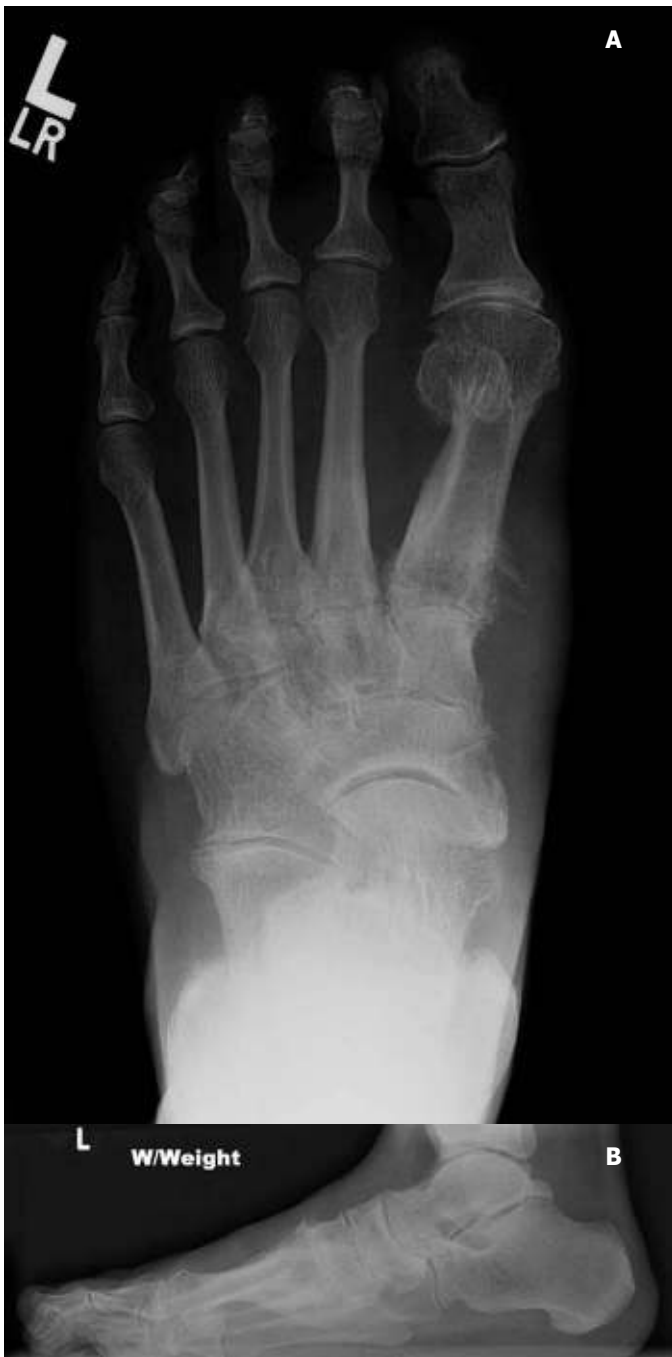

Figure 1A and 1B Initial anterior posterior (AP) (A) and lateral (B) radiographs demonstrating soft tissue edema with early signs of osteolysis, cortical thickening, fragmentation, and osseous destruction within the tarsometatarsal and naviculocuneiform joints.

Total contact casts (TCC) have been shown in numerous studies to be an effective immobilization device in the treatment of acute Charcot neuroarthropathy.^{5,7-14,16-20}

It is recommended that TCCs be changed frequently in order to prevent cast irritation, ulceration and to maintain immobilization as edema subsides. Minor complications such as skin irritation are anticipated with TCC. The risk of major complications such as ulceration and infection can be minimized with proper application techniques, as well as frequent casts changes, which permit careful monitoring, and adequate patient education.²⁷ Many centers have specially-trained orthotists who apply TCCs on a routine basis. Most studies support changing TCCs for the treatment of Stage I Charcot neuroarthropathy every 1-2 weeks.^{11,13,17,19,22,27-31} Some institutions have allowed weight bearing in the TCC due to its inherent stability with success in preliminary reports.^{9, 27-31}

Although weight bearing during stage I of Charcot neuroarthropathy is controversial, many patients tend to be non-compliant. This is because this period of prolonged non-weight bearing may be detrimental in quality of life and may pose to be an unacceptable disability.^{32,33} While the alternative may be amputation, advances in immobilization technology may allow protected weight bearing during the early stages of Charcot without the development of severe deformity.^{34,35} The purpose of this study was to report results of acute Stage 1 Charcot neuroarthropathy in individuals immobilized in a vacuum stabilization boot that maintained full weight bearing.

Case Series

Three consecutive patients presented with acute Stage I Charcot neuroarthropathy over a three month period (November 2009 to January 2010). All three patients had Brodsky type I deformity involving the tarsometatarsal and naviculocuneiform joints.¹⁸ Patients were referred for examination and treated within two weeks of symptom onset. Clinical examination revealed erythema, warmth, and edema involving the midfoot with gross instability, crepitation with midfoot range of motion, and bounding pedal pulses. One patient had diabetic neuropathy while the other two were diagnosed with alcoholic neuropathy. Peripheral neuropathy was confirmed by the absence to detect the Semmes-Weinstein 10gm monofilament.

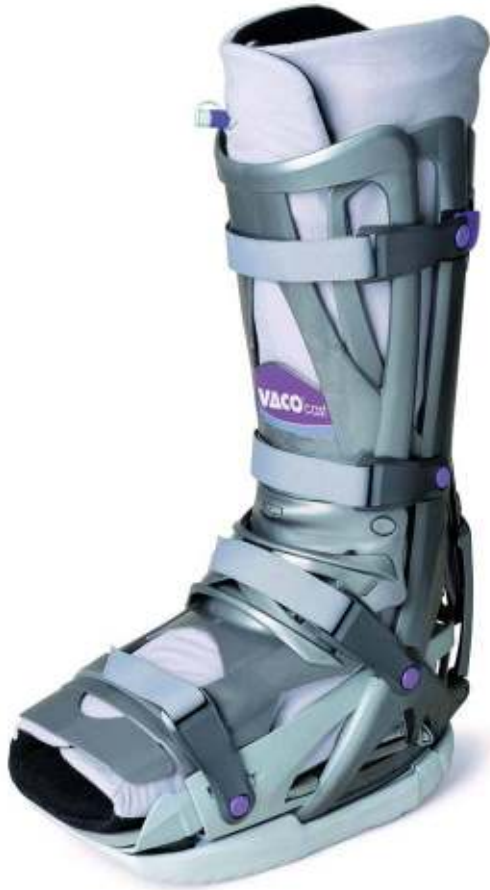

Figure 2 In this boot, by removing air from a vacuum cushion, small beads contour around the lower limb and create vacuum stabilization.

Two of the three patients reported a minor injury preceding the Charcot event. The third patient had had previous amputations of digits two and three for localized osteomyelitis secondary to contiguous digital ulcerations. All three patients were male with a mean age of 48.7 (range 46-53) years. All patients presented within two weeks of first symptoms and were ulcer free at the time of initial presentation with this being their first occurrence of Charcot neuroarthropathy. Radiographs were obtained with findings consistent with early signs of Charcot neuroarthropathy. (Fig. 1A and 1B) Magnetic resonance (MR) imaging further confirmed the diagnosis with diffuse bone marrow edema adjacent to the Lisfranc joint.

All three patients were treated with immobilization in a vacuum stabilization boot (VACOcast®, OPED Inc, Framingham, MA) with instructions to remain strictly non-weight bearing. (Fig. 2) Despite these recommendations, all three patients reported bearing weight on the affected limb in order to prevent loss of their job. All three patients were sole providers in their household with jobs that required extensive manual labor. The patients were compliant in wearing the boot at all times as this was verified through inspecting the undamaged compliance locks on the boot.

Serial monitoring was conducted by clinical examinations and plain radiographs. Patients were kept immobilized in the vacuum stabilization boot until resolution of edema, warmth (examined by palpation with back of hand and fingers and comparing to contra-lateral limb), and clinical stability was achieved. Successive radiographs were taken to ensure the absence of deformity progression every 3-4 weeks. (Fig. 3A, 3B and 3C) Throughout the treatment period each patient maintained normal full weight bearing in the conduct of their full-time jobs.

Patients wore the vacuum stabilization boot for a mean of 90.3 days (range 76 – 133 days). One patient developed a superficial abrasion on the dorsal proximal interphalangeal joint of the second digit. This healed after two weeks of wound care and the additional of padding to the boot in this area. There were no other complications experienced. During the treatment of acute Stage I Charcot neuroarthropathy, all three patients remained ulcer and callus free while ambulating in the immobilization boot. Once the Charcot events had progressed to the consolidation phase, patients were transitioned to accommodative shoes or boots with supportive inserts.

Two of the three patients were compliant with accommodative shoes and molded insoles. After 16 months from the initial presentation, both patients have not developed ulcers, callus, or progression of deformity. (Fig. 4A, 4B and 4C) During the 12 weeks that the third patient was wearing the immobilization boot, the deformity did not progress and the patient remained ulcer and callus free.

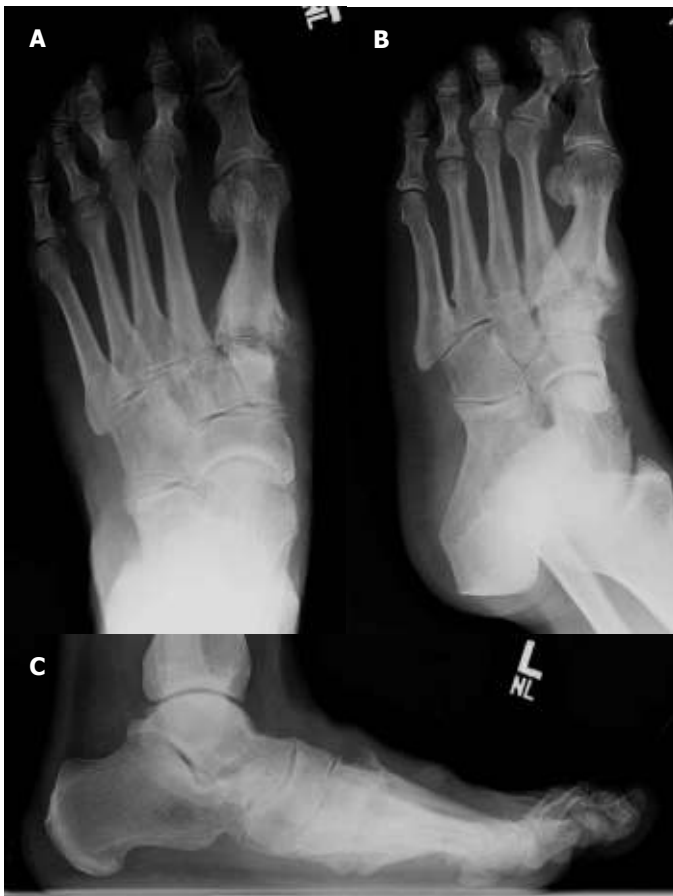

Figure 3A, 3B and 3C Progression of acute phase of Charcot neuroarthropathy. AP (A), Oblique (B) and lateral (C) views demonstrate increased osseous destruction and osteolysis.

However, the third patient did not obtain prescribed accommodative shoes or inserts citing financial limitations. He was subsequently lost to follow-up for five months after completing 12 weeks of immobilization therapy. His Charcot neuroarthropathy had developed a rocker bottom foot deformity and plantar midfoot ulcer after five months of interrupting care.

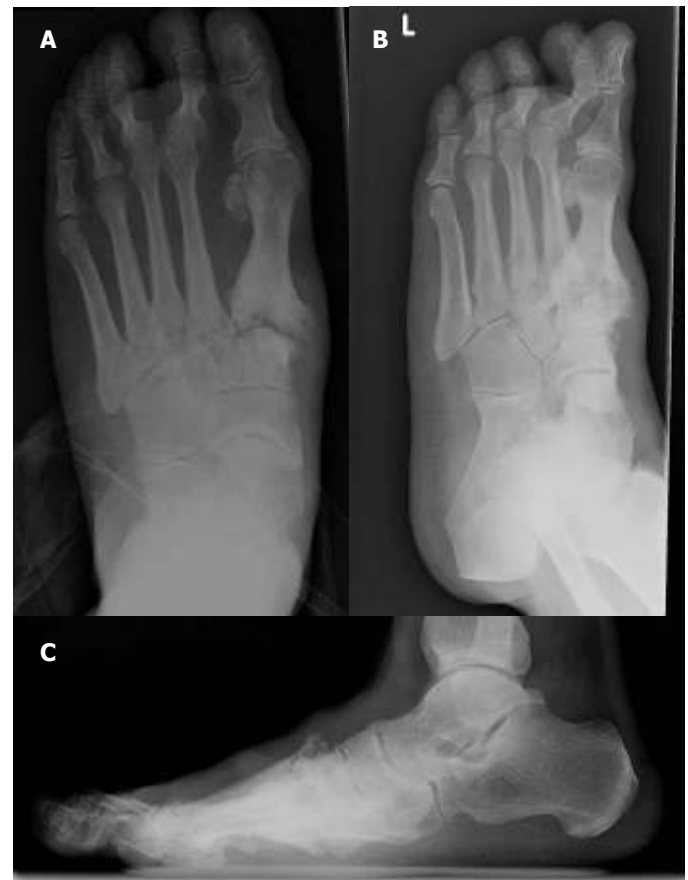


Figure 4A, 4B and 4C AP (A), Oblique (B) and lateral (C) views showing progression into chronic Charcot neuroarthropathy with maintenance of anatomic alignment with consolidation of osseous destruction.

Discussion

Management of Charcot neuroarthropathy is a complex process which requires flexibility and constant attention. This small case series demonstrates that despite the overt disregard for non-weight bearing management instructions, all patients were able to maintain employment and prevent progression of rocker bottom midfoot deformities during acute Eichenholtz stage I Charcot neuroarthropathy as there was continuous utilization of the vacuum immobilization boot.

Patients were continuously immobilized in a vacuum stabilizing below-knee boot with compliance confirmed by boot locks. There were minimal complications during the acute phase treatment with one patient developing a superficial digital abrasion from the boot. This was identified immediately and rectified by adjusting the boot. Despite fully weight-bearing, a rocker bottom deformity was prevented with adequate and constant immobilization.

Standard of care for acute Eichenholtz stage I traditionally includes total contact casting and complete non-weight bearing to prevent progression of deformity. This has been recently challenged by allowing weight bearing in the total contact cast in combination with frequent cast changes and close monitoring. Two prospective case series have reported successfully preventing deterioration of osseous alignment from acute phase Charcot deformity with weight-bearing total contact casts.^{28,29}

The amount of non-restrained cumulative load forces across acute Charcot joints is also believed to increase the amount of deformity progression. By immobilizing the foot with a walking total-contact cast, the acute phase resolved and further progression towards a rocker bottom foot was prevented.³⁰

The immobilization boot reported in this study was chosen for several reasons. Total contact casts require frequent changes and proper construction to prevent complications related to this casting technique. This immobilization boot had the advantage of clinical efficiency as no time was necessary beyond properly sizing and fitting the patient and providing instructions on its use. The vacuum boot can be adjusted to accommodate changes in edema. The removable sole allows patients to sleep with the boot without dirtying the linens. It also has a radiolucent frame that permits radiographic evaluation without removal. Finally, the compliance locking straps prevent unknown patient removal. Although none of the affected limbs had an open ulcer necessitating daily care, had local wound care been necessary by a visiting nurse an additional key would have been provided.

Limitations of this study include its retrospective nature. The initial treatment plan did not permit patients to weight bear during acute phase Charcot neuroarthropathy, however, weight bearing did not adversely impact the treatment outcome. Both mechanical and comparative studies are needed to further investigate the ability of nontraditional immobilization devices to effectively prevent osseous deformity in a disease which can cause permanent disability and eventual amputation. Future prospective studies with a larger sample size are needed to assess the long-term outcomes of this immobilization technique. Comparison studies of different immobilization techniques would also be very useful. Finally, the definition of adequate immobilization needs further investigation in order to achieve a balance of prevention of serious Charcot-related complications and quality of life.

Conclusion

Patients with acute Eichenholtz stage I midfoot Charcot neuroarthropathy were able to fully weight bear and maintain manual labor employment without development of a rocker bottom foot deformity while wearing a vacuum stabilization below-knee boot. Advances in immobilization therapy may allow improvement in the quality of life in acute phase Charcot neuroarthropathy.

References

1. Holewski, J, Moss KM, Stess RM, Graf PM, Grunfeld C. Prevalence of foot pathology and lower extremity complications in a diabetic outpatient clinic. *J Rehab Res and Devel* 1989 26: 35-44.
2. Sohn MW, Stuck RM, Pinzur M, Lee TA, Budiman-Mak E. Lower-extremity amputation risk after charcot arthropathy and diabetic foot ulcer. *Diabetes Care* 2010 33: 98-100.
3. van der Ven A, Chapman CB, Bowker JH. Charcot neuroarthropathy of the foot and ankle. *J Am Acad Orthop Surg* 2009 17: 562-571.
4. Sohn MW, Lee TA, Stuck RM, Frykberg RG, Budiman-Mak E. Mortality risk of Charcot arthropathy compared with that of diabetic foot ulcer and diabetes alone. *Diabetes Care* 2009 32: 816-821.
5. Boulton AJ, Jeffcoate WJ, Jones TL, Ulbrecht JS. International collaborative research on Charcot's disease. *Lancet* 2009 J373 (9658): 105-106.

6. Shibuya N, La Fontaine J, Frania SJ. Alcohol-induced neuroarthropathy in the foot: a case series and review of literature. *J Foot Ankle Surg* 2008 47: 118-124.
7. Nielson DL, Armstrong DG. The natural history of Charcot's neuroarthropathy. *Clin Podiatr Med Surg* 2008 1: 53-62.
8. Frykberg RG, Belczyk R. Epidemiology of the Charcot foot. *Clin Podiatr Med Surg* 2008 1:17-28.
9. Pinzur MS. Current concepts review: Charcot arthropathy of the foot and ankle. *Foot Ankle Int* 2007 8: 952-959.
10. Sanders LJ. What lessons can history teach us about the Charcot foot? *Clin Podiatr Med Surg* 2008 1: 1-15.
11. Wukich DK, Sung W. Charcot arthropathy of the foot and ankle: modern concepts and management review. *J Diabetes Complications* 2009 23: 409-426.
12. Jeffcoate WJ. Charcot neuro-osteoarthropathy. *Diabetes Metab Res Rev* 2008 24 (Suppl 1): S62-65.
13. Petrova NL, Edmonds ME. Charcot neuro-osteoarthropathy-current standards. *Diabetes Metab Res Rev* 2008 24 (Suppl 1): S58-61.
14. Chantelau E. The perils of procrastination: effects of early vs. delayed and treatment of incipient Charcot fracture. *Diabet Med* 2005 22: 1707-1712.
15. Eichenholtz SN. *Charcot Joints*. Springfield, Illinois: Charles C. Thomas, 1966.
16. Shaw JE, His WL, Ulbrecht JS. The mechanism of plantar unloading in total contact casts: implications for design and clinical use. *Foot Ankle Int* 1997 18: 809-817.
17. Pinzur MS, Shields N, Trepman E, Dawson P, Evans A. Current practice patterns in the treatment of Charcot foot. *Foot Ankle Int* 2000 21: 916-920.
18. Brodsky JW. The diabetic foot. In: Coughlin MJ, Mann RA, editors. *Surgery of the Foot and Ankle*. Vol 2. 7th ed. St. Louis, Mosby. 1999, 895-969.
19. Pinzur MS, Shields N, Trepman E, Dawson P, Evans A. Current practice Patterns in the treatment of Charcot foot. *Foot Ankle Int* 2000 21: 916-920.
20. Armstrong DG, Todd WF, Lavery LA, Harkless LB, Bushman TR. The natural history of acute Charcot's arthropathy in a diabetic foot specialty clinic. *Diabetic Med* 1997 14: 357-363.
21. Molines L, Darmon P, Raccach D. Charcot's foot: newest findings on its pathophysiology, diagnosis and treatment. *Diabetes Metab* 2010 36: 251-255.
22. Pinzur, MS. Surgical vs. accommodative treatment for Charcot arthropathy of the midfoot. *Foot Ankle Int* 2005 25: 545-549.
23. Myerson MS, Henderson MR, Saxby T, Short KW. Management of midfoot diabetic neuroarthropathy. *Foot Ankle Int*. 1994 15: 233-241.
24. Alpert SW, Koval KJ, Zuckerman JD. Neuropathic arthropathy: review of current knowledge. *J Am Acad Orthop Surg*. 1996 4: 100-108.
25. Fabrin J, Larsen K, Holstein PE. Long-term follow-up in diabetic Charcot feet with spontaneous onset. *Diabetes Care* 2000 23: 796-800.
26. Schon LC, Easley ME, Weinfeld SB. Charcot neuropathy of the foot and ankle. *Clin Orthop Relat Res* 1998 349: 116-131.
27. Wukich DK, Motko J. Safety of total contact casting in high-risk patients with neuropathic foot ulcers. *Foot Ankle Int* 2004 25: 556-560.
28. Pinzur MS, Lio T, Posner M. Treatment of Eichenholtz stage I Charcot foot arthropathy with a weightbearing total contact cast. *Foot Ankle Int* 2006 27: 324-329.
29. de Souza LJ. Charcot arthropathy and immobilization in a weight-bearing total contact cast. *JBJS* 2008 90A:754-759.
30. Kimmerle R, Chantelau E. Weight-bearing intensity produces charcot deformity in injured neuropathic feet in diabetes. *Exp Clin Endocrinol Diabetes* 2007 115: 360-364.
31. Chantelau E, Kimmerle R, Poll LW. Nonoperative treatment of neuro-osteoarthropathy of the foot: do we need new criteria? *Clin Podiatr Med Surg* 2007 24: 483-503.
32. Pakarinen TK, Laine HJ, Mäenpää H, Mattila P, Lahtela J. Long-term outcome and quality of life in patients with Charcot foot. *Foot Ankle Surg* 2009 15: 187-191.
33. Sochocki MP, Verity S, Atherton PJ, Huntington JL, Sloan JA, Embil JM, Trepman E. Health related quality of life in patients with Charcot arthropathy of the foot and ankle. *Foot Ankle Surg* 2008 14: 11-15.
34. Verity S, Sochocki M, Embil JM, Trepman E. Treatment of Charcot foot and ankle with a prefabricated removable walker brace and custom insole. *Foot Ankle Surg* 2008 14: 26-31.
35. Stöckle U, König B, Tempka A, Südkamp NP. Cast immobilization or vacuum stabilizing system? Early functional results after osteosynthesis of ankle fractures. *Unfallchirurg* 2000 103: 215-219.