



Swivel-type Dislocation of the Talonavicular Joint: A case report

by Eric Powell, DPM¹ ✉, Matthew LaBella, DPM, FACFAS² ✉

The Foot and Ankle Online Journal 4 (6): 3

Dislocation of the talonavicular joint is a rare occurrence. The swivel subtype dislocation is reported throughout the literature. Most are the result of an abductory or adductory force applied to the forefoot. Most authors report good functional results after a myriad of treatment options. Presented is a case of a 46 year-old male who sustained a medial swivel type dislocation of the talonavicular joint with concomitant fractures of the navicular and cuboid after a low-energy axial load to the foot. The case discusses some of the common issues revolving around the care of this type of dislocation.

Key words: Talonavicular joint dislocation.

Accepted: May, 2011

Published: June, 2011

This is an Open Access article distributed under the terms of the Creative Commons Attribution License. It permits unrestricted use, distribution, and reproduction in any medium, provided the original work is properly cited. ©The Foot and Ankle Online Journal (www.faoj.org), 2011 All rights reserved.

Talonavicular joint (TNJ) dislocation is a rare injury of the foot and ankle with most reported cases occurring after major trauma. The joint complex is surrounded by a strong network of ligaments and tendinous structures that aid in the strength of this joint in the prevention of injury. When a dislocation occurs to this joint, it is considered a serious injury due to the instability that can occur across Chopart's joint.

Main and Jowett described this dislocation type injury occurring at the midtarsal joints with a classification system to help the physician decide the best course of treatment. (Table 1)¹

A subtype pattern of injury is the swivel dislocation at the talonavicular joint. A medial or lateral directed force to forefoot can result in a swivel dislocation at the talonavicular joint. There are few studies that discuss this type of injury pattern.^{1,4,10} The following is a description of a patient who sustained an isolated talonavicular joint dislocation and subsequent treatment.

Address correspondence to: Eric Powell, DPM
710 Broadway, Seattle, WA 98122.

¹Resident Podiatric Physician, Swedish Podiatric Surgical Residency-Swedish Medical Center 710 Broadway, Seattle, WA 98122.

²Attending Podiatric Physician, Swedish Podiatric Surgical Residency-Swedish Medical Center 710 Broadway, Seattle, WA 98122.

Direction of Deforming Force	Resulting displacement/Deformity	Prognosis
Medial	Fracture-Sprains, fracture-subluxation/dislocation and swivel	Good
Longitudinal	Undisplaced fractures of the navicular, displaced fractures of the navicular, crushing injuries to the navicular, cuneiforms and talus.	Lateral longitudinal: poor Medial Longitudinal: good
Lateral	Fracture-sprains, fracture-subluxations and swivel	Poor
Plantar	Fracture-sprains and fracture-subluxation/dislocations	
Crush	No constant pattern of injury	Variable
Dorsal	None described	

Table 1 Main and Jowett Classification for Midtarsal joint injuries.

Case Report

A 46 year-old male presented to the Emergency Department (ED). The patient sustained an injury to the right foot after getting down from a bunk bed. The patient stated that he landed on his right foot sustaining an axial load as the foot flexed and inverted. There was immediate pain to the foot and the patient was unable to bear any weight. Standard three view non-weightbearing radiographs were obtained in the ED showing a medial dislocation of the navicular on the talus, isolated to the talonavicular joint. (Figs. 1A and 1B) The clinical examination revealed no neurovascular deficit and the skin and soft tissue envelope was not under tension. His past medical history indicated he had bipolar affective disorder.

The decision was made to perform a closed reduction in the ED. The patient was placed under conscious sedation and the dislocation was manually reduced by first accentuating the deformity, then distracting axially with counter pressure proximally and finally reducing the distal foot back into its natural position. (Figs. 2A and 2B) It was noted that upon relocation, a pop was felt and the foot appeared realigned relative to the injury and compared with the contralateral foot. Neurovascular status was intact to the foot after reduction. He was placed into a standard posterior splint after the reduction as opposed to a cast. This was done because there was concern the patient's foot would swell causing cast pain and entrapment.

A computerized tomography (CT) scan was obtained which showed a comminuted, non-displaced, non-intraarticular fracture of the cuboid and navicular as well as a medial talar head impaction fracture. (Figs. 3A and 3B) Explicit instructions were dispensed for the patient to remain non-weightbearing to the injury foot.

A follow-up one week later revealed that the patient had been noncompliant and walked on the foot. Radiographs confirmed that the foot was again dislocated. The decision was then made to perform a closed reduction with percutaneous fixation of the dislocation. Standard operating protocols were followed and the patient's deformity was manually reduced intra-operatively. A Steinman pin was placed into the navicular and used as a joystick. Two 0.62 K-wires were driven percutaneously across the talonavicular joint for stabilization. (Figs. 4A and 4B) The K-wires were removed at six weeks. (Figs. 5A and 5B) Immediately after the K-wire removal, the joint was stressed under fluoroscan and deemed stable. He remained weightbearing in a CAM boot. Two weeks after the k-wire removal, the joint remained stable. He was slowly transitioned from CAM boot to regular shoe gear over a period of three weeks. He has remained full, unprotected weightbearing without complication to date.

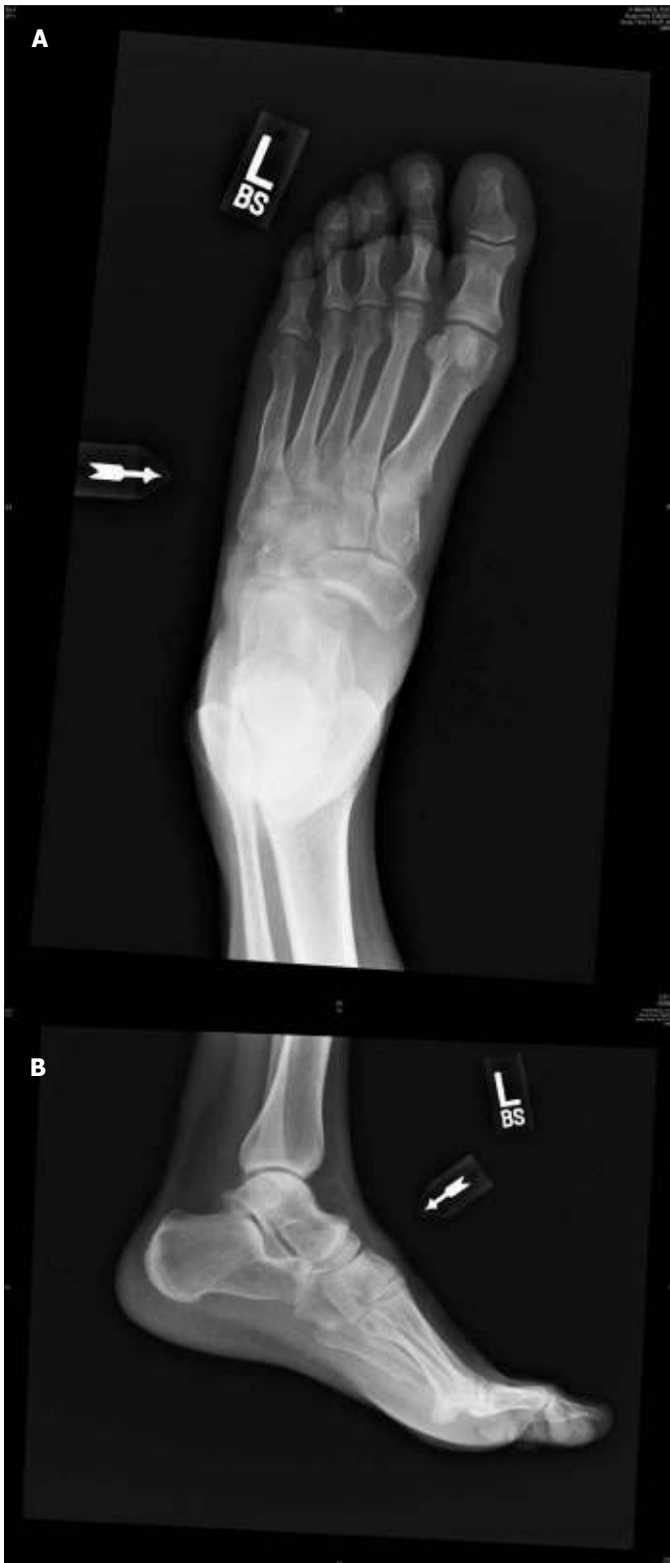

Figure 1A and 1B Anteroposterior (A) and Lateral (B) view of the original injury.

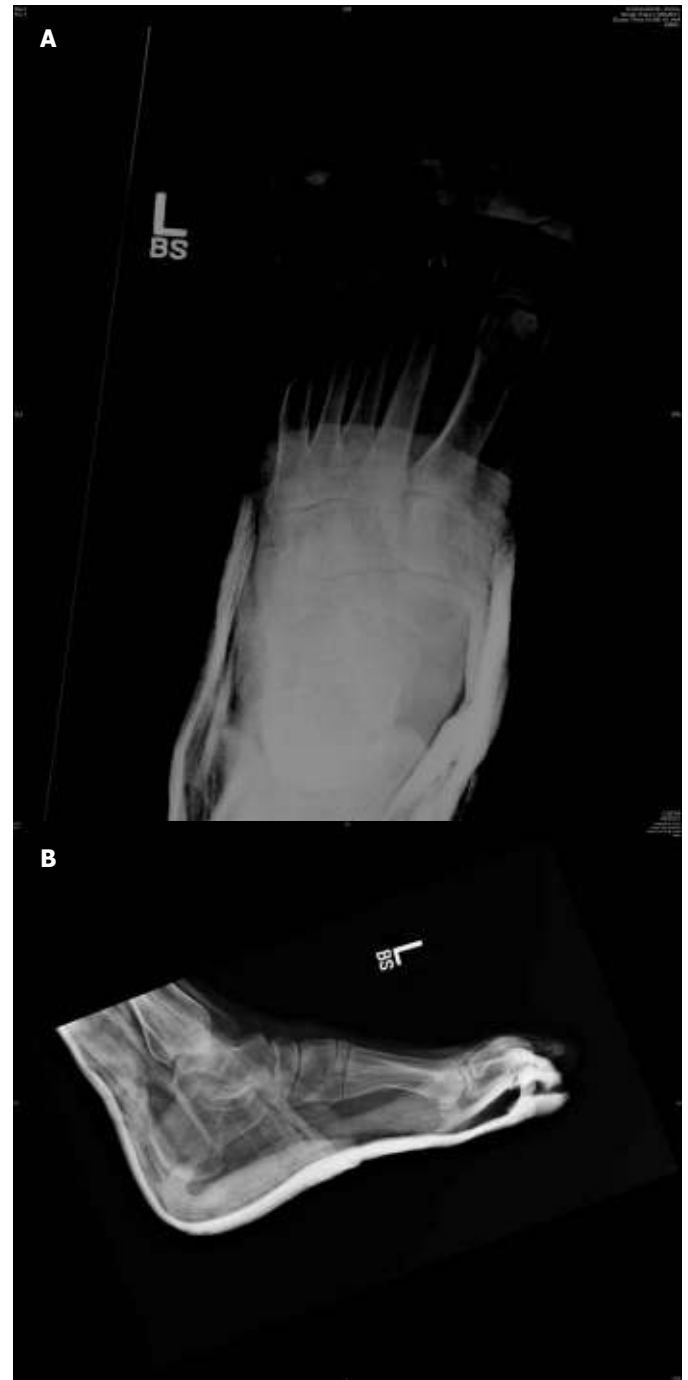


Figure 2A and 2B Anteroposterior view after initial closed reduction in the Emergency Department. (ED) (A) Lateral view after initial closed reduction in the ED. (B)

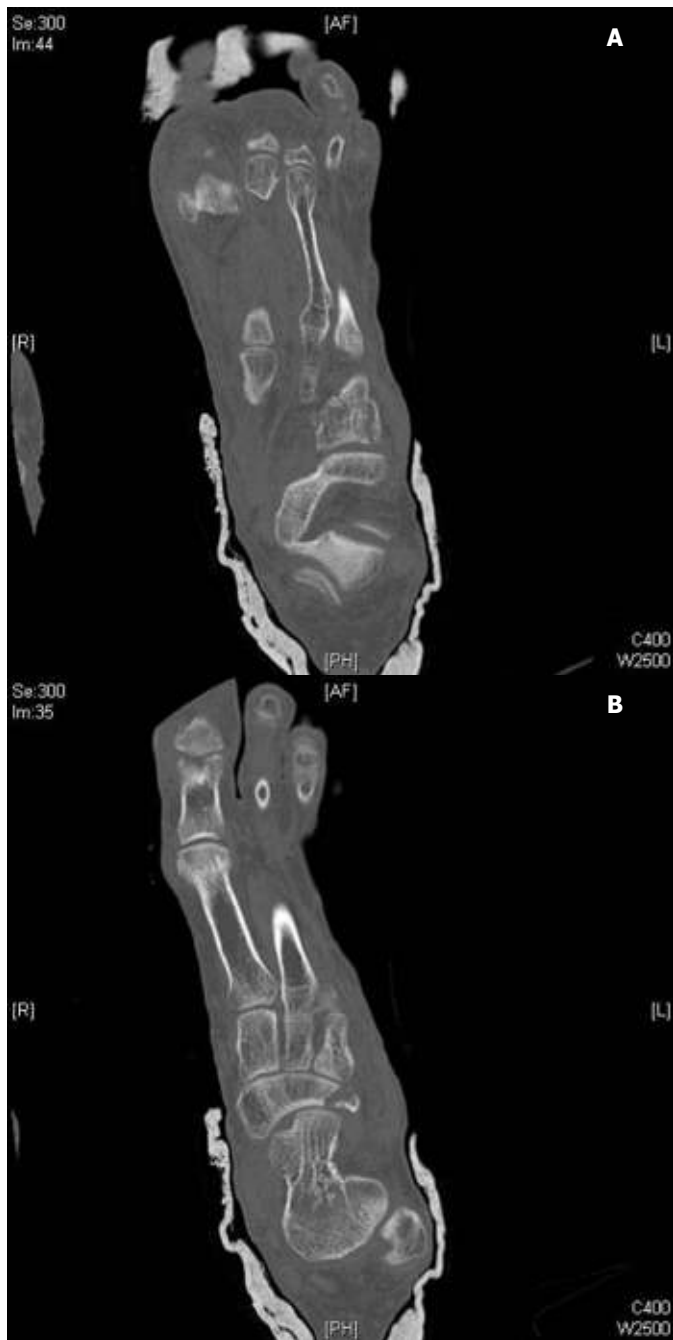

Figure 3A and 3B Axial computed tomography (CT) showing the cuboid fracture. (A) Axial CT showing the navicular fracture and the talar head impaction fracture. Post initial closed reduction. (B)

He reports no pain or disability to the joint complex with ambulation at the latest follow-up. At his latest scheduled appointment, five months after the initial injury, the patient did not return for follow-up and was not able to be contacted for further evaluation. No evidence of avascular necrosis or delayed healing has been appreciated to date.

Discussion

TNJ dislocation is a rare injury of the foot and ankle with most cases reported occurring after major trauma. Medial TNJ dislocation, like the one described, are among the more common types of deformity occurring at the TNJ after trauma with a prevalence of 30%.² Jowett and Main devised a classification scheme based on the direction of force to the foot.¹ (Table 1) Based on the radiographic and CT evaluation, the fracture sustained in our case is a medial swivel type. The treatment of choice for severe injuries to the midtarsal joint is immediate reduction of the deformity.

A study evaluating 110 Chopart joint dislocations were analyzed by Richter, et al.⁵ They stratified the injuries based on treatment into four categories: closed reduction, no internal fixation; closed reduction with internal fixation; open reduction, internal fixation, optional additional external fixation; amputation. The injuries amenable to closed reduction with no internal fixation were pure Chopart joint dislocations without related fracture. This cohort study consisted of 19 patients (17%). Compared to the other methods of treatment, the closed reduction without internal fixation group did not show a significantly worse outcome than the other groups. Furthermore, the AOFAS scores at follow-up were not significantly different between the groups.³

In another series, 18 patients sustained injuries to the talonavicular joint. Thirteen were medial, 5 were lateral. Of the medial, 11/13 was closed. The 11 were closed reduced under conscious sedation. 10 were excellent results at follow-up and one was fair. The two open were reduced and pinned with k-wires.

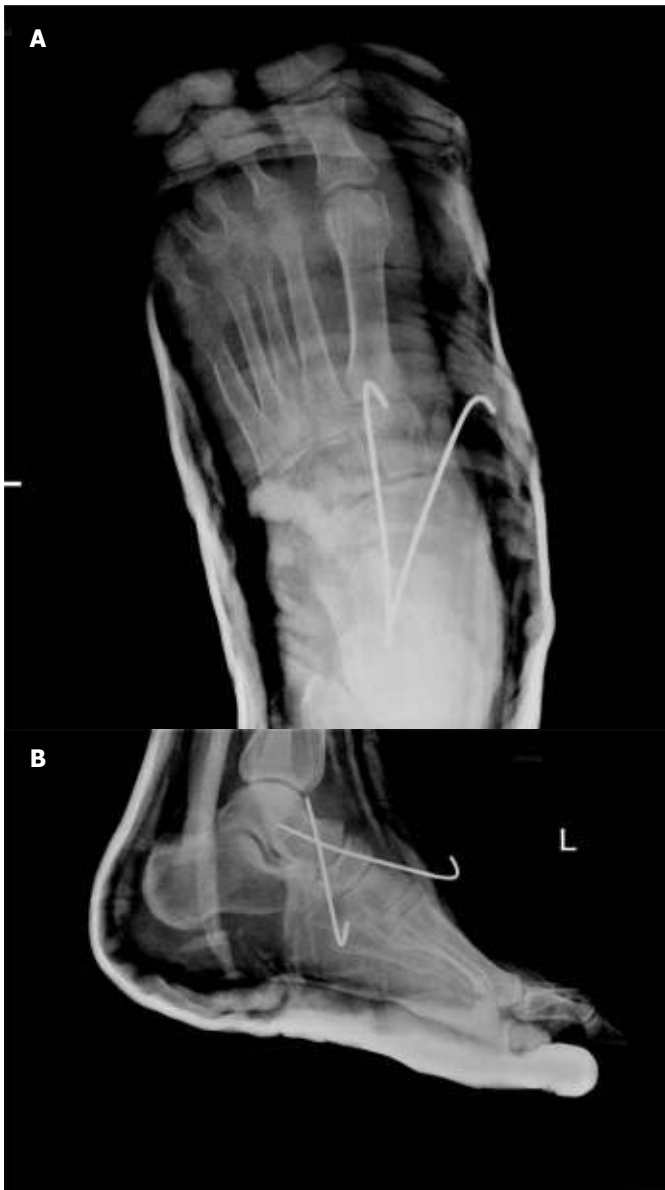

Figure 4A and 4B Anteroposterior (A) and Lateral (B) view after percutaneous pinning using K-wires.

One was fair and one was poor, owing to the extent of the injury. They recommend that low energy, medial dislocations are most amenable to closed reduction with a poorer prognosis with either open dislocations or lateral dislocations.⁴ Van Dorp, et al., had a small cohort of seven patients with varying degree of Chopart's injury. AOFAS scores averaged 72 in their group and 4/7 were pain free after a minimum of six-months of follow-up.⁹

However, the distinction between open reduction versus closed reduction was not elucidated, therefore few conclusions can be drawn from this study.

A single patient case study by Pehlivan, et al., described an isolated medial dislocation at the TNJ. The injury was from a low energy mechanism, but resulted in buttonholing of the talar head through the extensor retinaculum. The deformity had to be openly reduced in the operating room. The percutaneous fixation was removed at six weeks after surgery. The patient was transitioned to regular shoe gear over the following two week period after fixation removal. At latest follow-up, the patient had little residual functional defect, however, lateral column pain with long distance ambulation was the only significant complaint.¹¹

Most authors advocate the use of internal fixation for stabilization of the acutely dislocated Chopart joint.^{2,3,5,6} Richter, et al., advocates that all dislocations at the TNJ be treated with open reduction and internal fixation due to the potential for vascular compromise.⁵ Williams, et al., described closed reduction without the need for percutaneous fixation in a single case report with a low energy mechanism for a medial swivel pattern. The dislocation was reduced intraoperatively and under stress radiograph evaluation, was deemed to be stable. She was placed into a cast after reduction. The patient's only complaint was her inability to dance as well after injury than prior to injury.¹³

In the evaluation of such injuries, an important factor to consider is the mechanism of injury/deforming force. Swivel type injuries are associated with fewer complications than pure dorsal dislocations due to a lesser degree of ligamentous structure involvement and preservation of plantar ligament integrity. Very few attempts should be made at closed reduction of the deformity.^{2,6} If the surgeon is unable to obtain proper reduction, then one must have a low threshold for further, more aggressive reduction; surgical closed reduction with percutaneous k-wire or screw fixation, open reduction with internal fixation, external fixation or, in severe cases, primary amputation.⁷

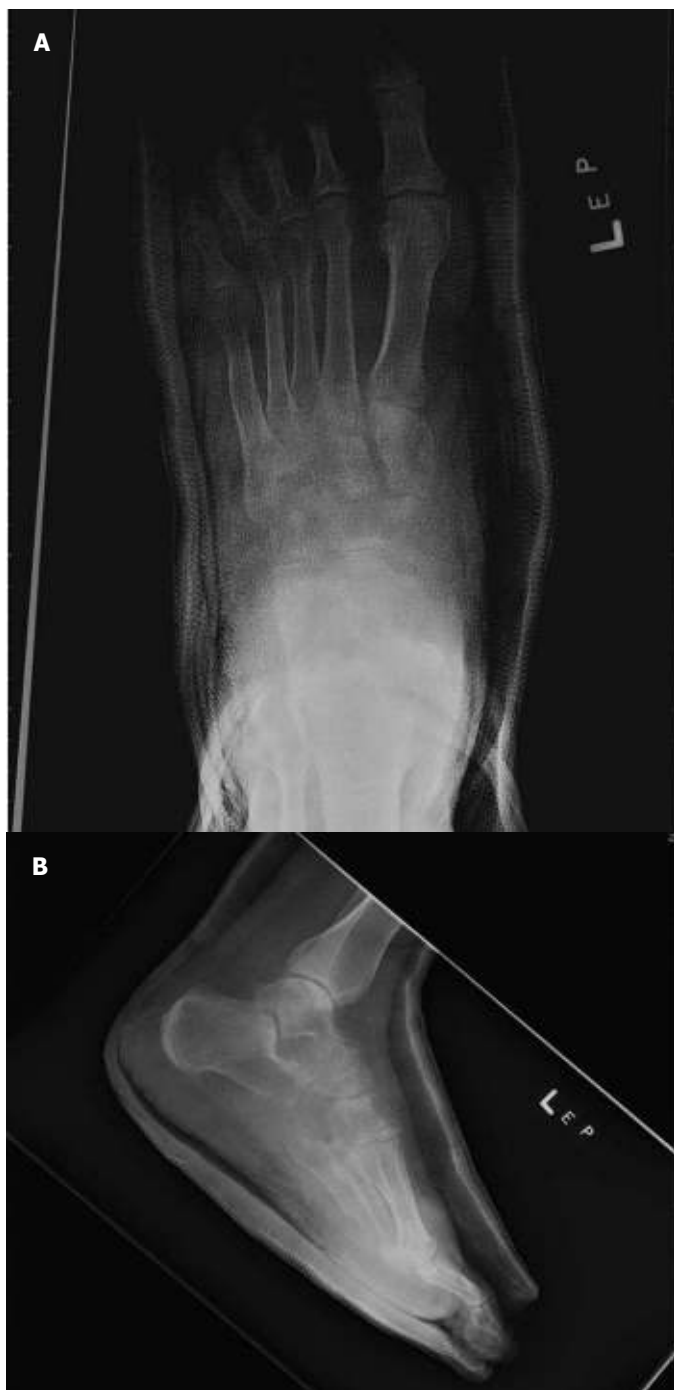

Figure 5A and 5B Anteroposterior (A) and lateral (B) radiographic view after K-wire removal.

Further considerations in treatment are timing of injury to presentation, neurovascular deficit, integrity of the soft tissue envelope and proper imaging.⁸

The prevalence of concomitant injury with talonavicular joint dislocations is quite high, in upwards of 75-90%.⁹ Other studies have described coexisting injury with TNJ dislocation.^{2,10,11} Our patient also sustained navicular, cuboid and talar head fractures. It was felt that these injuries did not need to be fixated since they were non-displaced and not intraarticular. Ip and Lui suggests that concomitant ligamentous injury carries a worse prognosis than coexisting fractures alone.⁶ The ability of the patient to remain non-weightbearing on the foot is essential for a good outcome. In retrospective evaluation, the threshold for surgery may have been too high for our case. A full and thorough history and physical is imperative for proper treatment, but the physician must always remember to evaluate the social component; as each patient will require their own, unique set of parameters for care.

References

1. Main BJ, Jowett RL. Injuries of the midtarsal joint. *JBJS* 1975 57B: 89-97
2. Miller CM, Winter WG, Bucknell AL, Jonassen EA. Injuries to the midtarsal joint and lesser tarsal bones. *J Am Acad Orthop Surg* 1998 6: 249-258
3. Richter M, Thermann H, Huefner T, Schmidt U, Goesling T, Krettek C. Chopart joint fracture-dislocation: Initial Open reduction provides better outcome than closed reduction. *Foot Ankle Int* 2004 25: 340-348.
4. Garofalo R, Moretti B, Ortolano V, Cariola P, Solarino G, Wettstein M, Mouhsine E. Peritalar dislocations: A retrospective study of 18 Cases. *J Foot Ankle Surg* 2004 43: 166-172.
5. Richter M, Wippermann B, Krettek C, Schrott HE, Hufner T, Thermann H. Fractures and fracture dislocations of the midfoot: Occurrence, causes and long-term results. *Foot Ankle Int* 2001 22: 392-398.
6. Ip K, Lui TH. Isolated dorsal midtarsal (Chopart) dislocation: a case report. *J Orthop Surg* 2006 14: 357-359.
7. Samoladas E, Fortiades H, Christoforides J, Pournaras J. Talonavicular dislocation and nondisplaced fracture of the navicular. *Arch Orthop Trauma Surg* 2005 125: 59-61
8. Klaue K. Chopart fractures. *Injury Int J Care Inj* 2004 35B: 64-70.
9. Van Dorp KB, de Vries MR, van der Elst M, Schepers T. Chopart joint injury: A study of outcome and morbidity. *J Foot Ankle Surg* 2010 49: 541-545.

10. Datt NS, Rao AS, Rao DV. Medial swivel dislocation of the talonavicular joint. *Ind J Orthop* 2009 43: 87-89.
11. Pehlivan O, Akmaz I, Solakoglu C, Rodop O. Medial peritalar dislocation. *Arch Orthop Trauma Surg* 2002 122: 541-543.
12. Puthezhath K, Veluthedath R, Kumaran CM, Patinharayil G. Acute isolated dorsal midtarsal (Chopart's) dislocation: A case report. *J Foot Ankle Surg* 2009 48: 462-465.
13. Williams DF, Hanoun A, Hakimi M, Ali S, Khatri M. Talonavicular dislocation with associated cuboid fracture following low-energy trauma. *Foot Ankle Surg.* 2009 15: 155-157.