



# Hardware Related Pain and Hardware Removal after Open Reduction and Internal Fixation of Ankle Fractures

by Johan H. Pot<sup>1</sup>✉, Remco J.A. van Wensen<sup>1</sup>, Jan G. Olsman<sup>1</sup>

The Foot and Ankle Online Journal 4 (5): 1

**Objectives:** To assess the incidence of hardware related pain after open reduction and internal fixation (ORIF) after ankle fractures through functional outcomes scores in patients with or without hardware related pain.

**Design:** Retrospective study.

**Setting:** Regional trauma center.

**Patients:** One hundred and seventy six patients undergoing ORIF of an ankle fracture with a minimal follow up of 18 months were sent questionnaires. In total, 80 responding patients were available for analysis.

**Main Outcome Measurements:** Visual Analog Pain Score, Foot and Ankle Outcome Score (FAOS).

**Results:** In seventeen patients (21%), the hardware was removed because of pain. In another seventeen patients (21%), the hardware was not removed, but pain was reported. Patients with hardware related pain had significantly worse functional outcome scores than patients without hardware related pain. After elective hardware removal, pain reduction was achieved in 71 % of the patients. Mean Visual Analog Score was 7.0 before and 3.9 after elective hardware removal for pain.

**Conclusions:** Hardware related pain is a significant issue after ORIF of ankle fractures. Patients with hardware related pain have significantly worse functional outcome scores. Although pain reduction is achieved in 71% of the patients after elective hardware removal, a substantial number of patients have persistent complaints. Patients should be well informed about the expectations and risks of elective hardware removal.

**Key words:** Hardware, hardware removal, hardware related pain, ankle fracture, ORIF ankle, FAOS.

Accepted: April, 2011

Published: May, 2011

This is an Open Access article distributed under the terms of the Creative Commons Attribution License. It permits unrestricted use, distribution, and reproduction in any medium, provided the original work is properly cited. ©The Foot and Ankle Online Journal ([www.faoj.org](http://www.faoj.org)), 2011 All rights reserved.

Fractures of the distal tibia and fibula are one of the most common types of fractures in adults.<sup>1</sup> Whereas stable and non or minimally displaced fractures can be treated with cast immobilization, unstable dislocated ankle fractures require open reduction and internal fixation (ORIF) with plate and screws.

**Address correspondence to:** Johan Pot, Jeroen Bosch Hospital, Location Groot Ziekengasthuis, Postbus 90153, 5200 ME 's-Hertogenbosch, The Netherlands. Email: [johanhpot@gmail.com](mailto:johanhpot@gmail.com)

<sup>1</sup> Jeroen Bosch Hospital, 's-Hertogenbosch, the Netherlands. Department of Surgery, Postbus 90153, 5200 ME 's-Hertogenbosch The Netherlands. tel: (+31) 73-6992000; fax:(+31) 73-6992163.

Long term functional outcome is satisfying in most patients, but a number of patients have persistent 'hardware related' complaints and tenderness that 'require' elective hardware removal. Aside from painful hardware, some asymptomatic patients also want their hardware removed for other reasons. Although hardware removal is frequently undertaken, it is not without risk and the results are often unpredictable.<sup>2</sup>

The more commonly reported risks of hardware removal are iatrogenic (nerve) injury, infections, delay in wound healing and re-fractures. In addition to medical considerations there is also an economic impact such as physician costs, hospital fees, patient loss of work and productivity.<sup>2</sup> Reports in literature are not consistent concerning the incidence of painful hardware and the outcome and pain relief after hardware removal.<sup>3-5</sup> This study was designed to document the incidence of late pain after ORIF of ankle fractures and to analyse the outcome, expectations and complications after hardware removal.

### Patients and Methods

In October 2010, all patients with surgically treated unstable ankle (malleolar) fractures between April 2007 and April 2009 were reviewed. A total number of 176 patients were included with a minimum follow up of 18 months assuming the end stage of rehabilitation after the ankle fracture was achieved. Demographic data, patient's age, sex and medical history, were obtained from the hospital database and clinical notes. All patients were sent a questionnaire. One part consisted of the Foot and Ankle Outcome Score (FAOS) which is designed to assess a number of foot and ankle related problems. It consists of 5 subscales; Pain, other Symptoms, Function in daily living (ADL), Function in sport and recreation (Sport) and foot and ankle-related Quality of Life (QOL). The second part of the questionnaire consisted of specific questions about pain at the site of the hardware material and specific questions about the removal of osteosynthesis material. Patients that underwent elective hardware removal were asked to indicate pain before and after hardware removal by a Visual Analog Scale (VAS) pain score. Surgical stabilization consisted of open reduction and internal fixation (ORIF).

All surgeries were performed in the Jeroen Bosch Hospital, a 600 bed teaching hospital, by or under direct supervision of one of the trauma surgeons. AO-fixation material was used including small-fragment plates and screws and sometimes K-wires on the fibula or tibia if necessary. Fixation of the posterior malleolus was performed if more than one-third of the joint surface on the lateral radiograph was affected. Syndesmotic fixation was performed in cases of widened mortises on stress-testing after ORIF. Most of the time, one hook test was performed.

Postoperative therapy was overall direct functional and non-weight bearing for a minimum of six weeks. Sometimes a below-the-knee plaster cast was applied for 1 week due to wound protection. After 6 weeks, patients were allowed to bear weight as tolerated and were referred for outpatient physical therapy if necessary. Patients that were treated with a syndesmotic screw remained non-weight bearing until the syndesmotic screw had been removed. According to one of the trauma-surgeons, weight bearing was allowed after 6 weeks without removal of the syndesmotic screw. Indications for hardware removal include infection, failure of osteosynthesis material, severe pain and tenderness on the location of hardware and specific demands in asymptomatic patients. Before the procedure was performed, fracture consolidation was assessed by a radiograph. Functional outcome scores for each FAOS subscale were correlated with the presence of local pain. Statistical analysis was performed by using the Student *t* test. Results were considered significant if  $p < 0.05$  in a 2-tailed analysis.

### Results

The questionnaire was sent to 176 patients. The response rate was 46% ( $n=80$  patients). In the response group there were 24% males and the mean age was  $44 \pm 23$  years. The mean follow up was 30 months and 29 patients (36%) reported hardware removal. (Table 1) The indication for removal was pain or discomfort in 60% ( $n=17$ ).

	<b>N = 80</b>	<b>100%</b>	% of patients with hardware in situ
Hardware not removed	51	64%	
Hardware removed	29	36%	
Hardware removed because of pain	17	21%	
Painful hardware in situ	17	21%	33%
Pain free hardware	34	43%	67%
Pain at the site of hardware after ORIF	34	42%	

**Table 1** Patients with hardware removed and painful or painless hardware.

<b>Change in pain</b>	<b>Percentage of patients</b>	<b>N</b>
Pain-free	24%	4
Pain reduced	47%	8
No change in pain	29%	5
Pain increased	0%	0

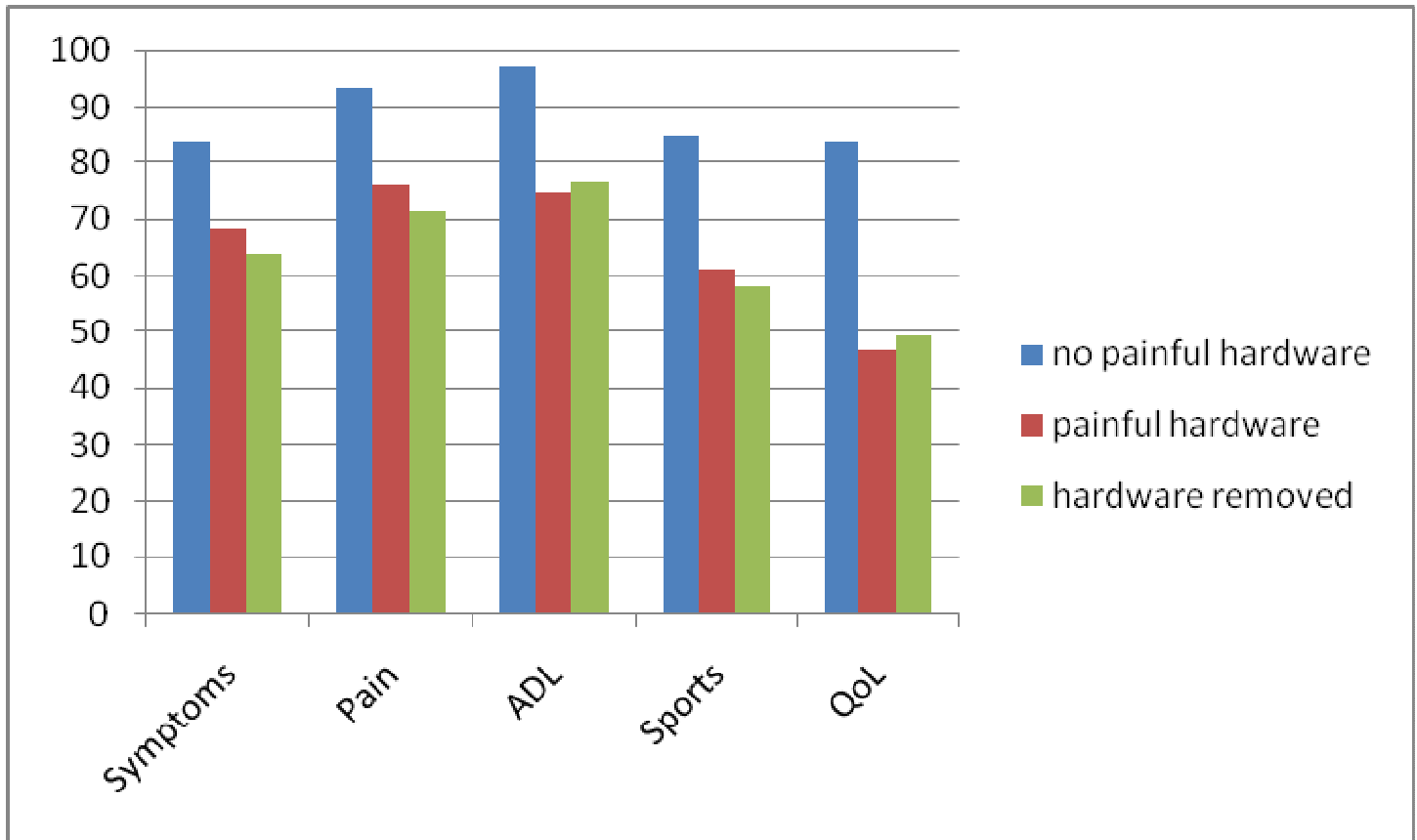
**Table 2** Change in pain after elective hardware removal (for painful hardware).

In one patient it was removed because of infection and syndesmotic screws were removed in 37% ( $n=11$ ) as a standard procedure before weight bearing was allowed. In patients that did not have osteosynthesis material removed ( $n=51$ ), 33 % had local pain or tenderness on the location of the osteosynthesis material. In total, 34 patients had pain at the hardware site after ORIF (42%). (Table 1)

FAOS score were compared between patients having local pain or tenderness overlying the hardware, patients who did not and patients that underwent hardware removal because of pain. Lower scores indicate a lower functional level and these scores are shown in Figure 1. The FAOS scores of patients without hardware related pain was significantly higher in all the 5 subscores. ( $P<0.05$ ) compared to patients with hardware related pain. Patients that underwent elective hardware removal however did not have significantly different scores than those with painful hardware.

In 71% of the patients that underwent elective hardware removal because of pain, reported a decrease of their complaints after hardware removal.

These patients had a mean pain VAS (visual analog scale) of 7.0 ( $\pm 2.1$ ) before hardware removal and a mean VAS of 3.9  $\pm 2.8$  after hardware removal. This was a significant pain reduction. ( $P<0.05$ ). However in 27% of the patients VAS scores did not change after elective hardware removal and only 24% became pain-free with a VAS of 0. (Table 2) Recovery time from the secondary surgery was approximately 9 weeks ( $\pm 10$ ). Range of motion improved in 56% of the patients, whereas 6 % reported a decreased range of motion after hardware removal. 39% of the patients did not notice any change in range of motion. In 20% of the patients a superficial wound infection was reported that required additional treatment. No re-fractures or pseudoarthrosis were reported. Furthermore 25 % of the patients reported new complaints after hardware removal, such as other pain or instability.



**Figure 1** FAOS scores of all patients with surgically treated ankle fractures. Patients without painful hardware have significantly higher FAOS score in all subscores compared to patients with hardware related pain (removed or not).

## Discussion

After a mean follow up of 2.5 years 21% of the patients reported to have their hardware removed because of pain and 21% of the patients had significant and specific local pain at the site of the hardware. Obviously, hardware is not always the main contributor of this pain as scar tissue, post-traumatic changes and malalignment can also play a role. This should not be underestimated by (orthopedic) trauma surgeons. One study found similar results with 31% painful hardware and 17% removal.<sup>4</sup> However other studies report lower rates of painful hardware<sup>6,7</sup>, especially among the elderly.<sup>8</sup> Patients with painful hardware and also patients who had their hardware removed have significantly lower functional scores than patients without complaints.

In fact, all FAOS subscores were significantly worse in these patients suggesting a serious impact on quality of life and on daily activities. This is supported by Brown, et al.,<sup>4</sup> who found significantly better outcome scores in patients that did not have hardware related pain. The results of hardware removal are comparable to Jacobsen, et al.,<sup>3</sup> who found a 75% improvement after hardware removal. Brown on the other hand found a pain reduction in only 50% of the patients. A success rate of 71% in this study appears to be a promising statistic. However, in 76% of patients, they do not become pain free and have persistent pain. Patients should be informed correctly about the significant risk of persistent pain.

Range of motion is similar or better in most patients, but 25% of the patient had new or other complaints after removal of the hardware. Other studies that do not specifically investigate hardware removal of the ankle but hardware removal in general find other results. A prospective review about outcome of different types of hardware in different body parts found a significant pain relief, improved function and improved SMFA scores (Short Musculoskeletal Function Assessment Questionnaire).<sup>5</sup> Hardware in ankles, however can lead to location specific problems due to mechanical characteristics of the ankle and the lack of surrounding tissue in the ankle. Indications for elective hardware removal could be a pitfall. Local tenderness and pain can be due to the hardware, but can also be caused by posttraumatic changes in the ankle. Hence the surgeon and patient should also be well informed about specific complaints and a radiograph is mandatory to evaluate posttraumatic changes. If in doubt, an intra-articular injection with a local anaesthetic can help to differentiate between intra articular (post traumatic) and extra-articular (e.g. hardware) causes. Arthroscopic evaluation can be useful to assess degenerative changes, intra-articular malalignments or to remove loose bodies or adhesions.

Routine removal of hardware in patients with surgically treated ankle fractures is not recommended, because most patients do not have hardware related pain or may have minimal symptoms. Not only would routine hardware removal lead to more complications, increased health care costs, lost work and productivity, it can also lead to new complaints or increased pain.<sup>2</sup>

The type of implant or material may influence the amount of hardware related symptoms. Obviously bulky implants are more likely to cause symptoms, but smaller implants can lead to bony overgrowth which makes hard removal more difficult. Intramedullary nailing may be beneficial in some fractures, because soft tissue is less manipulated and also these implants can be easier to remove.<sup>9</sup>

Biodegradable osteosynthetic material have been proposed as a new method to avoid a secondary procedure to remove the material.<sup>10</sup> Although materials are improving, clinical results thus far are not encouraging. Petrisor, et al., concluded that patients with biodegradable osteosynthesis material had a higher risk (OR 2.63) for adverse events, such as osteosynthesis failure, compared to metal implants in patients with ankle fractures.<sup>11</sup> Ahl, et al.,<sup>10</sup> found that patients treated with traditional titanium implants had better radiological measured stability, although clinical results did not differ. It is not clear whether these biodegradable materials result in less tenderness on palpation in short and long term.

## Conclusion

Hardware related pain is a big issue in patients with a surgically treated ankle fracture that must not be underestimated. Functional outcome scores are significantly worse in patients with hardware related pain. Pain reduction can be achieved in 71% of the patients with hardware related pain but only 24% of the patients became pain-free after hardware removal. Similar results were found in literature. The most important conclusion that can be drawn is that the patient should be informed correctly about the risks and expectations of this second operation.

## References

1. Daly PJ, Fitzgerald RH, Jr Melton LJ, Ilstrup DM. Epidemiology of ankle fractures in Rochester, Minnesota. *Acta Orthop Scand* 58: 539-544, 1987.
2. Busam ML, Esther RJ and Obrebsky WT. Hardware removal: indications and expectations. *J Am Acad Orthop Surg* 14: 113-120, 2006.
3. Jacobsen S, Honnens de Lichtenberg M, Jensen CM, Torholm C. Removal of internal fixation--the effect on patients' complaints: a study of 66 cases of removal of internal fixation after malleolar fractures. *Foot Ankle Int* 15: 170-171, 1994.
4. Brown OL, Dirschl D, Rand Obrebsky WT. Incidence of hardware-related pain and its effect on functional outcomes after open reduction and internal fixation of ankle fractures. *J Orthop Trauma* 15: 271-274, 2001.

5. Minkowitz RB, Bhadsavle S, Walsh M, Egol KA. Removal of painful orthopaedic implants after fracture union. *JBJS* 89A: 1906-1912, 2007.
6. Bostman O and Pihlajamaki H, Routine implant removal after fracture surgery: a potentially reducible consumer of hospital resources in trauma units. *J Trauma* 41: 846-849, 1996.
7. Michelson JD. Fractures about the ankle. *JBJS* 77A: 142-152, 1995.
8. Koval KJ, Zhou W, Sparks MJ, Cantu RV, Hecht P, Lurie J. Complications after ankle fracture in elderly patients. *Foot Ankle Int* 28: 1249-1255, 2007.
9. Guo JJ, Tang N, Yang HL, Tang TS. A prospective, randomised trial comparing closed intramedullary nailing with percutaneous plating in the treatment of distal metaphyseal fractures of the tibia. *JBJS* 92B: 984-988, 2010.
10. Ahl T, Dalen N, Lundberg A, Wykman A. Biodegradable fixation of ankle fractures. A roentgen stereophotogrammetric study of 32 cases. *Acta Orthop Scand* 65: 166-170, 1994.
11. Petrisor BA, Poolman R, Koval K, Tornetta P 3rd, Bhandari M; Evidence-Based Orthopaedic Trauma Working Group. Management of displaced ankle fractures. *J Orthop Trauma* 20: 515-518, 2006.