



Maduramycosis of the Foot: A case report of Boyd's Amputation as a salvage procedure in late presentation

by Mohan Kumar, J.¹✉, Narayana Gowda, B.S.²

The Foot and Ankle Online Journal 4 (3): 2

With the increased movement of the world population, familiarity with the clinical picture of the Madura foot is of growing importance beyond its original endemic areas. The characteristic triad of symptoms consists of indurated swelling, multiple sinus tracts with purulent discharge filled with grains and localization at the foot. An increasing number of new etiologic agents are recognized today. For a better choice of therapy an adequate diagnostic procedure is essential; a deep biopsy for histology appears to give a more substantial contribution to identification of the causal organism than culture. The treatment which should be started early is at first essentially a drug treatment. However, in spite of high expectations with regard to new antimycotic drugs, amputation or disarticulation is often inevitable even today, particularly when the lesion is caused by Eumycetes. We present a case of eumycotic mycetoma with extensive involvement of foot for which a Boyd's amputation was done and treated with antifungal therapy with no recurrence.

Key words: Osteomyelitis, amputation, Mycetoma, Madura foot.

Accepted: February, 2011

Published: March, 2011

This is an Open Access article distributed under the terms of the Creative Commons Attribution License. It permits unrestricted use, distribution, and reproduction in any medium, provided the original work is properly cited. ©The Foot and Ankle Online Journal (www.faoj.org), 2011 All rights reserved.

Mycetoma is a chronic localized infectious and granulomatous disease involving subcutaneous skin and bone. It results in various deforming sequelae.¹ It is a granulomatous infection of the dermal and subcutaneous tissues caused by filamentous aerobic and anaerobic bacteria (actinomycetomas), true fungi (eumycetomas), and true bacteria, such as *Staphylococcus aureus* and *Pseudomonas* species (botryomycosis).^{2,3} Mycetoma of the foot was first described by Colebrock in 1846 in the Indian district of Madura, and is commonly known as Madura foot.⁴

The infectious organism is presumed to be directly inoculated after penetration of the skin with a sharp object, such as a thorn. Clinically it presents with painless subcutaneous nodules and fistulae from which a purulent exudate may be discharged. Histologically the nodules contain microabscesses and a surrounding granulomatous reaction. The treatment which should be started early is at first a drug treatment. However, in spite of high expectations with regard to new antimycotic drugs, amputation or disarticulation is often inevitable even today, particularly when the lesion is caused by Eumycetes.

Address correspondence to: Dr. Mohan Kumar, PESIMSR, Kuppam, India.
Mob:09703326378

¹ Consultant in Arthroscopy & Sports Medicine, PESIMSR, Kuppam, India.

² Ortho (Diploma in orthopaedics), DNB Ortho (Diplomate of national board) Assistant professor, Dept of Orthopaedics, PESIMSR, Kuppam, India.

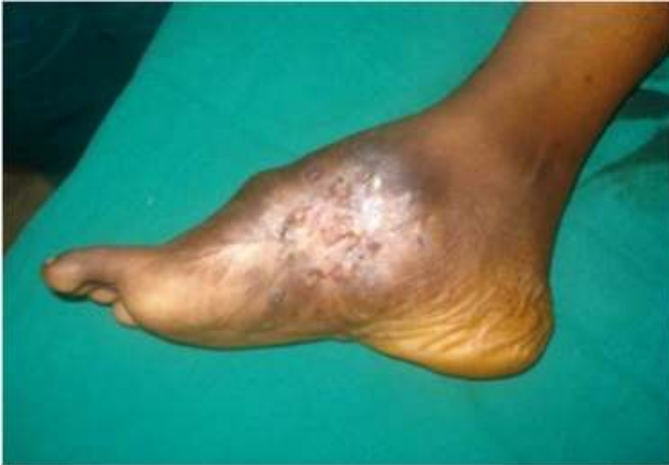

Figure 1 Clinical photograph of Madura foot.

Although the clinical picture is characteristic, diagnostic confusion may occur with chronic bacterial osteomyelitis, especially when bone destruction has occurred. Botryomycosis can give a similar picture. This is a chronic bacterial infection caused by gram positive cocci (Staphylococci, Streptococci) and gram negative bacteria (Escherichia coli, Pseudomonas, Proteus) that can lead to subcutaneous swelling and draining fistulas. Like mycetoma, grains (colonies of bacteria) can be found in suppurative discharges and biopsy specimens. In botryomycosis however, organs can be affected too. Neoplasms (benign and malignant) should be excluded as well.

In the foot, amputation between the tarsometatarsal level and the level of the Syme procedure results in an equinus deformity due to imbalance between tendons acting at the ankle. Boyd's operation retains the calcaneus and fuses it with the tibia in the ankle mortise.⁵ It provides an excellent weight-bearing stump with no need for an artificial limb, but it has been discarded because of difficulty in obtaining sound calcaneotibial fusion.⁶

Recent literature suggests that all mycetomas may be amenable to medical treatment, particularly since the introduction of newazole – derivatives like itraconazole and ketoconazole.⁷

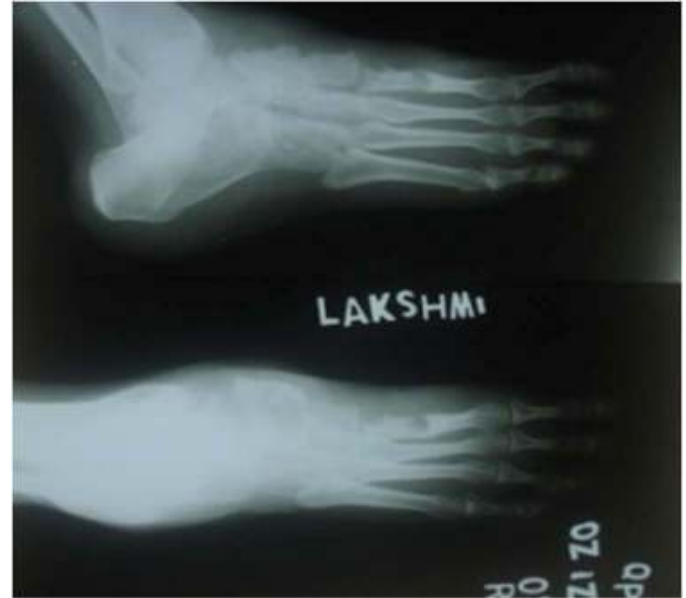

Figure 2 Radiograph of Madura foot with a multiple lytic lesions in tarsal and metatarsal bones.

Case Report

A 35-year-old woman from Tamil Nadu, India presented with a 24 month history of a steadily growing lump in the region of the first metatarsophalangeal joint of her right foot. She was treated elsewhere with first ray amputation and itraconazole for 2 months, but patient came to us with multiple sinuses with discharging black granules. (Fig. 1) General examination was unremarkable with no lymphadenopathy or other soft tissue masses. Though the clinical picture was characteristic, differential diagnoses of chronic bacterial osteomyelitis, botryomycosis were also considered.

Blood and serum chemistry were unremarkable. Plain radiographs showed a soft tissue swelling with no calcification. (Fig. 2) An Ultrasound showed a hypoechoic lesion containing discrete hyperechoic foci). In the magnetic resonance imaging (MRI) scan, the lesion was seen on T1 and T2 weighted sequences, to be composed of multiple lesions of high signal intensity measuring a few millimeters across. (Fig. 3)

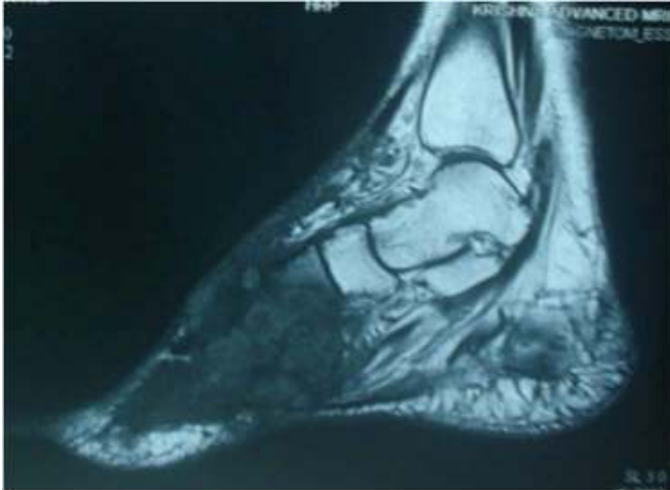


Figure 3 MRI showing multiple lesions of high signal intensity measuring a few millimeters across involving all the metatarsal and tarsal bones except the calcaneus.

A biopsy was performed under ultrasound guidance. Histological features were suggestive of an inflammatory condition with no clear evidence of malignancy. Since the disease was chronic in nature and the patient had taken antifungal treatment for a very long time with no signs of resolution, we planned for an amputation. We discussed in detail the patient's options including below knee, Syme's and Boyd's amputation. A wide excision was performed due to extensive soft tissue tumor and Boyd's amputation was performed. A talectomy and calcaneo-tibial arthrodesis was performed by using a Charnley's compression device. (Figs. 4A and 4B) Histological examination of the resected tissue revealed chronic inflammation with visible fungal hyphae.

The patient was treated with oral itraconazole for 10 months, 200 mg three times daily for one week followed by 200 mg once daily. The patient has been followed for 14 months without evidence of recurrence. The patient was monitored regularly with routine investigations, renal function tests and liver function tests at every three months during treatment. The patient did not develop any of the side effects of long term use of itraconazole. The patient has been followed for 14 months without evidence of recurrence. (Figs. 5 and 6)

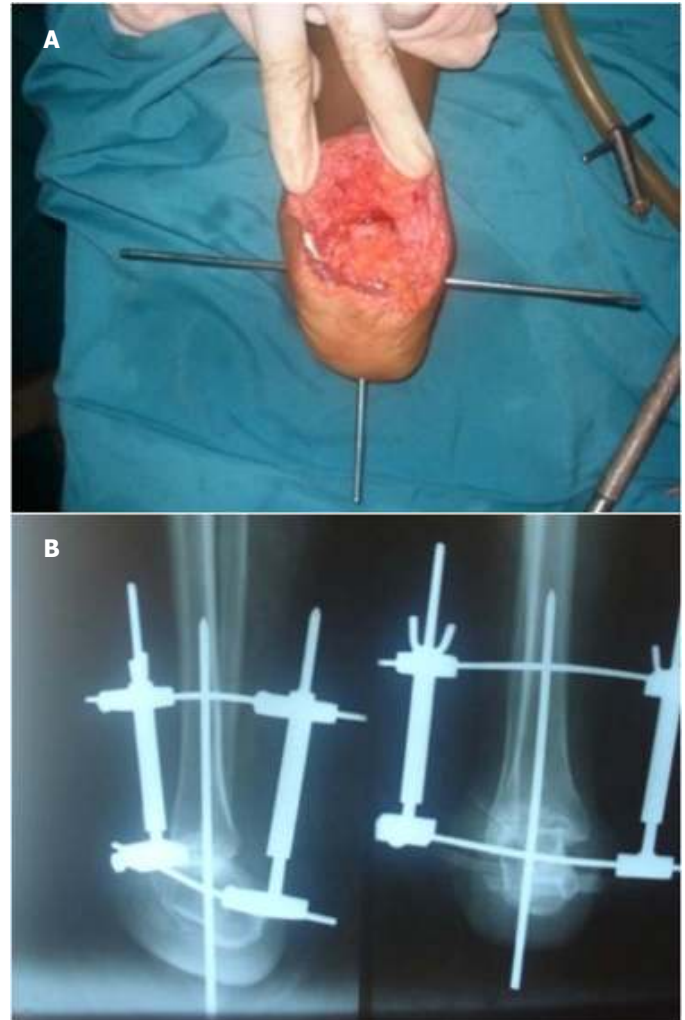


Figure 4A and 4B Intraoperative photo showing tibio-calcaneal arthrodesis stabilized with a Steinman pin. (A) Immediate post-operative radiograph showing Charnley's compression device in place to stabilize the arthrodesis.

Discussion

Mycetomas are frequent in the tropical zones of America (Mexico and Venezuela), Africa (Senegal, Sudan) and Asia (India), but can also be observed beyond these areas. Bidie and Carter gave a full description of the disease. Dieng, et al., report 130 cases of mycetoma in Senegal from 1983 to 2000.

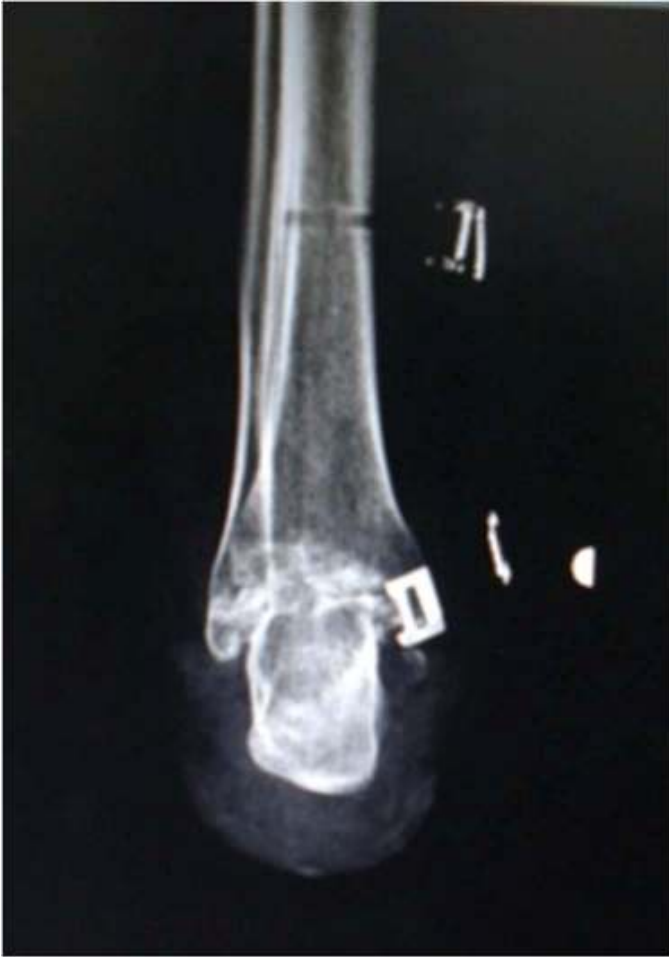

Figure 5 Boyd's amputation 6 months after surgery showing functional os calcis.

Treatment was medical for actinomycetoma and surgical for eumycetoma. Lesions were located on the foot in 81 patients. Sixty six patients with actinomycetoma were cured by medical treatment. Distinction between eumycetoma and actinomycetoma is very important for the treatment.¹⁰

Actinomycetoma is amenable to treatment by antibiotics, preferably by combined drug therapy for long periods. Eumycetoma is usually treated by aggressive surgical excision combined with medical treatment.¹¹ Without proper treatment, mycetoma can lead to deformity, amputation, and death.¹²

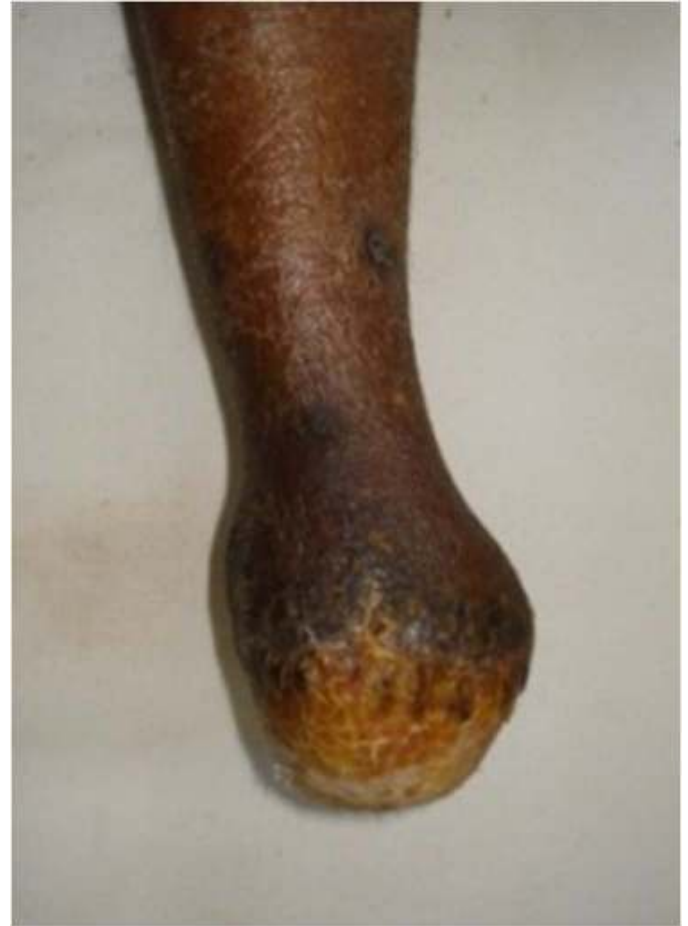

Figure 6 Boyd's amputation 6 months after surgery showing functional stump.

It is essential to start the treatment at an early stage. Several recorded eumycetomas appear to respond well to administration of antifungal therapy. In our case however, there was a recurrence probably due to inadequate clearance and inadequate antifungal therapy. We performed a Boyd's amputation and instituted antifungal therapy with Itraconazole. Boyd's operation has advantages over Syme's amputation in terms of walking, foot stability, and rebalancing. Also, backward migration of the heel fat pad and shortening that may occur long term in Syme's amputation is not seen in Boyd's operation.¹³

After 14 months of follow-up, there was no evidence of recurrence. The stump of the Boyd amputation has sound plantar skin with good blood supply and sensation.

References

1. Shadomy HJ, Utz JP. Deep fungal infection. In Fitzpatrick TB, Eisen AZ, Wolff (eds). *Dermatology in General Medicine*. 4th edition New York, McGraw Hill 1993, 2472-2475.
2. Lupi O, Tying SK, McGinnis MR. Tropical dermatology: fungal tropical diseases. *J Am Acad Dermatol* 2005 53: 931-951.
3. Picou K, Batres E, Jarratt M. Botryomycosis: a bacterial cause of mycetoma. *Arch Dermatol* 1979, 115: 609-610.
4. Magana M, Magana M. Mycetoma. In Demis DJ (ed). *Clinical Dermatology*. 26th edition. Philadelphia: Lippincott Williams and Wilkins. 1999, section 17-24, 1-22.
5. Boyd HB. Amputation of the foot with calcaneotibial arthrodesis. *JBJS* 1939 21: 997-1000.
6. Mills KL. *Guide to Orthopaedics*. Volume I. Edinburgh, Churchill Livingstone Ltd, 1981.
7. Ruxin T, Steck W, Helm T, Bergfeld W, Bolwell B. *Pseudallescheria boydii* in an immunocompromised host, Successful treatment with debridement and itraconazole. *Arch Dermatol* 1996, 132: 382 – 384.
8. Cathrine AN, Bhattacharya K, Srinivasan V. Mycetoma leg a-- case report. *Int J Low Extrem Wounds*. 2003 2(3): 171-172.
9. Sundaram C, Umabala P, Laxmi V, Purohit AK, Prasad VS, Panigrahi M, Sahu BP, Sarathi MV, Kaul S, Borghain R, Meena AK, Jayalakshmi SS, Suvarna A, Mohandas S, Murthy JM. Pathology of fungal infections of the central nervous system: 17 years' experience from Southern India. *Histopathology*. 2006 49(4): 396-405.
10. Dieng MT, Sy MH, Diop BM, Niang SO, Ndiaye B. Mycetoma: 130 cases. *Ann Dermatol Venereol* 2003 130(1 Pt 1): 16-9.
11. Fahal AH. Mycetoma: a thorn in the flesh. *Trans R Soc Trop Med Hyg* 2004 98(1): 3-11.
12. Lichon V, Khachemoune A. Mycetoma: a review. *Am J Clin Dermatol* 2006 7(5): 315-321.
13. Altindas M, Kilic A. Is Boyd's Operation a last solution that may prevent major amputations in diabetic foot patients. *J Foot & Ankle Surgery* 2008 47 (4): 307-312.