

# Reconstructing Limb Deformities using the VCAM™ External Fixator: A series of 3 cases

by Michael P. DellaCorte, DPM, FACFAS<sup>1</sup>✉, Panagiotis Panagakos, DPM<sup>2</sup>✉,  
Tarika Singh, DPM<sup>3</sup>✉, Howard Goldsmith, DPM, AACFAS<sup>4</sup>✉

The Foot and Ankle Online Journal 4 (1): 2

*External fixation was used almost exclusively for fracture management. It is also used for arthrodesis, management of lower extremity deformities such as Charcot neuroarthropathy, limb lengthening, osteotomy stabilization, osteomyelitis, nonunion or pseudoarthrosis. It has proven extremely useful in the treatment of a number of conditions because it can provide distraction, compression, stabilization and neutralization as needed. Traditional external fixators involve driving pins through the tibia and fibula. The VCAM™ is a unique below the ankle external fixator. The VCAM™ can avoid possible disruptions and complications that are often seen with traditional Ilizarov fixators. The indications for the VCAM™ external fixator are identical to the Ilizarov fixators, such as off-loading, fracture reduction and reconstructive procedures. In our institution, we have used the VCAM™ device to off-load ulcerations and correct limb deformities. In the cases presented in this paper the VCAM™ was used to off-load wounds secondary to Charcot arthropathy and transmetatarsal amputations, as well as to gradually correct a rearfoot deformity such as seen in a Chopart's amputation. The VCAM™ can be constructed into an Ilizarov type frame or a hybrid frame which can be used to achieve gradual triplanar correction. We have seen good results using the VCAM™ for wound care and limb deformities and recommend this approach when tibia and fibula intervention is not necessary.*

**Key words:** Limb deformity, Charcot foot, ulceration, VCAM™, wound, external fixation.

**Accepted:** December, 2010

**Published:** January, 2011

This is an Open Access article distributed under the terms of the Creative Commons Attribution License. It permits unrestricted use, distribution, and reproduction in any medium, provided the original work is properly cited. ©The Foot and Ankle Online Journal ([www.faoj.org](http://www.faoj.org))

External fixators have proven very versatile in treatment as they can be used with open, closed or limited open surgical techniques. They provide access to the involved limb for wound healing and dressing changes and can be designed to correct complex deformities such as Charcot joint. They allow for gradual, precise correction over the postoperative course rather than a single intra-operative correction by osteotomy or fusion.

**Send correspondence to:** Michael P. DellaCorte, DPM, FACFAS, Director of Podiatric Medical and Surgery Program at NorthShore Forest Hills LIJ; 5901 69<sup>th</sup> street, Maspeth, NY 11378. (718) 639-3338

<sup>1</sup> Director of Podiatric Medical and Surgery Program at NorthShore Forest Hills LIJ; 5901 69<sup>th</sup> street, Maspeth, NY 11378.

<sup>2</sup> PM&S 36 Resident; Hahnemann University Hospital.

<sup>3</sup> PM&S 36 Resident; Hahnemann University Hospital.

<sup>4</sup> Private Practice New York, NY.

Ring fixators are typically used to treat complex Charcot neuroarthropathy.<sup>1</sup> External fixators provide multiplanar correction including angulation, translation, rotation, stabilization, compression, distraction and neutralization while allowing for surrounding soft tissue adaptation; this also helps to minimize wound complications and vascular compromise that may result from overcorrection in a single-stage procedure.<sup>2,4,5,6</sup> In general, external fixators can be used to correct coexisting deformities separately, successively or simultaneously.<sup>3</sup>

The VCAM™ fixator allows for adjustment and alteration as needed during the post-operative period. Full immediate weight bearing postoperatively is also possible with the external fixator.<sup>2</sup> This is extremely important in Charcot reconstruction with concomitant ulcerations that require offloading. Additionally, external fixation is the only treatment option for Charcot with associated osteomyelitis or in Eichenholtz stage I and II, where internal fixation is contraindicated.<sup>4</sup>

There are two main types of fixators. The monolateral fixator which consists of threaded half-pins attached to a bar which allows for axial compression or distraction. The other main type is the ring fixator which was made popular by G.A. Ilizarov. The ring fixators use trans-osseous wires and pins placed under tension for bone fixation; they are more versatile and complex than the monolateral fixators. The hybrid fixator is a combination of these two main types and may be more appropriate for certain indications.<sup>2,3</sup>

Lower limb deformities secondary to trauma, diabetes or any other pathological cause can be devastating to patients and frustrate foot and ankle surgeons treating them. Charcot arthropathy is one of the limb deformities discussed in this paper that can lead to ulceration. Treatment of Charcot foot may require internal as well as external fixation. Ilizarov type fixators have been used for surgical reconstruction of this deformity. Surgery is indicated for treatment of Charcot arthropathy if chronic or recurrent ulcers are associated with the deformity, if the deformity is unstable and if there is an acute fracture in a neuropathic patient with good circulation.<sup>1,2</sup>

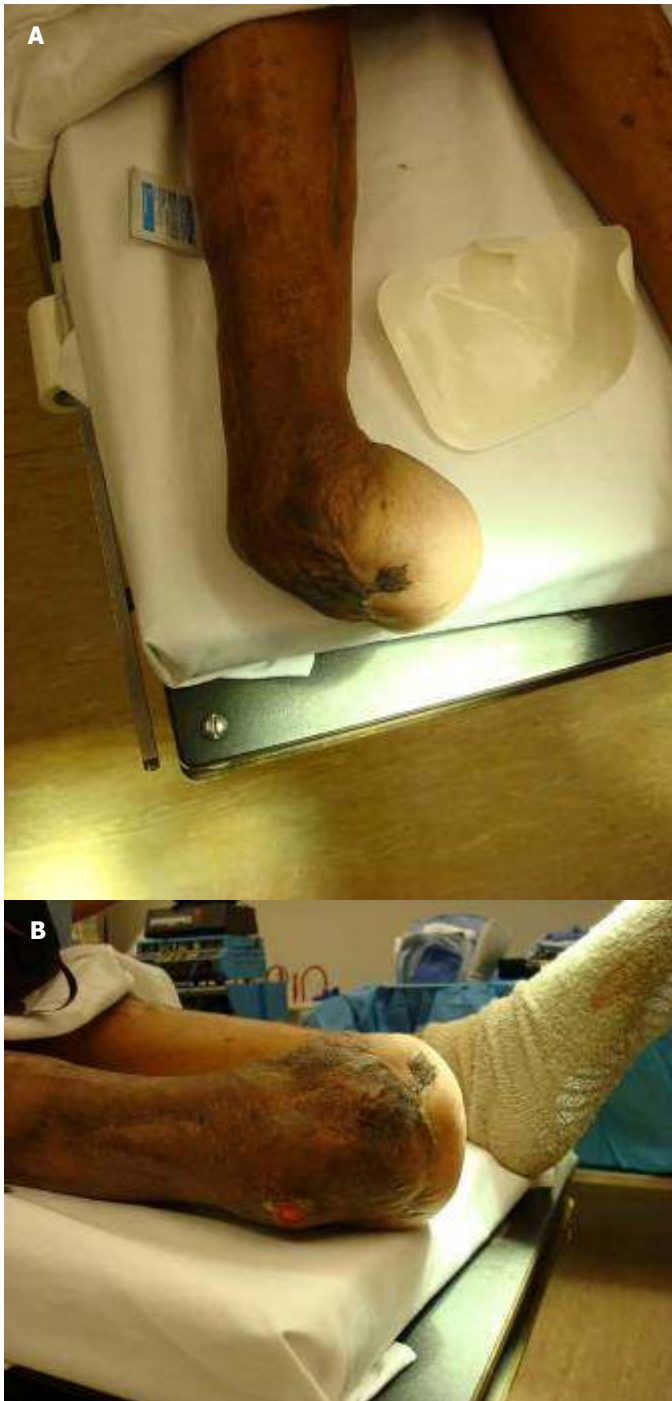
There is limited mention in the literature of external fixation devices that do not extend proximal to the ankle. The purpose of this paper is to introduce the VCAM™ external fixator and present its various uses and construct designs.

The VCAM™ has been available for nearly a decade. In our opinion it is an underutilized external fixator because it has not been previously reported in the literature which has led to an ignorance of the device in the orthopaedic community.

It has mainly been used in locations where ankle privileges are not available to podiatrists. The VCAM™ consists of a leg portion with a boot construct similar to a CAM walker with Velcro straps lined along the leg sleeve, plastic upright Velcro extensions attached to posts, various size threaded rods, half rings, foot plates and a rocker bottom with rubber treads with Velcro straps. We believe this unique external fixator has many advantages over traditional Ilizarov frames. It reduces the number of pins or wires placed across the tibia and fibula, therefore decreasing pin site infections, calf edema does not become an issue, fractures of the tibia and fibula when inserting, removing and/or tensioning the wires and decrease in thermal necrosis of neurovascular and muscular structures in the leg. The VCAM™ cannot be used for limb lengthening procedures, ankle fractures, pilon fractures, or any other surgical procedure involving the tibia or fibula

### Technique

When all ancillary pedal procedures are complete and the half rings and wires have been applied to the operative site and tensioned, the VCAM™ leg sleeve is first applied over cast-padding. Next, the plastic extensions are attached by velcro and are secured. Then three or four hole posts are secured to the plastic extensions to which various sized rods are attached spanning from the leg down to the foot. These rods are connected to the foot plate and half rings with the use of posts, if needed. Note that the foot plates and half rings are secured in place with nuts and bolts to the smooth olive transfixation wires during the surgical reconstruction. Lastly, the rubber rockerbottom foot attachment allows protection and partial weight bearing. Constructs are designed based on the pedal pathology present.



**Figure 1A and 1B** Case 1: Lateral aspect of the lower extremity with adducto-varus deformity and ulceration over the fibular malleolus before VCAM™ application. (A) A superior view of the lower extremity with adducto-varus deformity. (B)

Once there is clinical and radiographic evidence of consolidation at the fusion site, or there is clinical correction of a specific limb deformity the external fixator may be removed. The frame is often removed after 8 to 12 weeks and the patient is fitted for a Charcot Restraint Orthotic Walker (CROW) and remains in this device for 6 months.

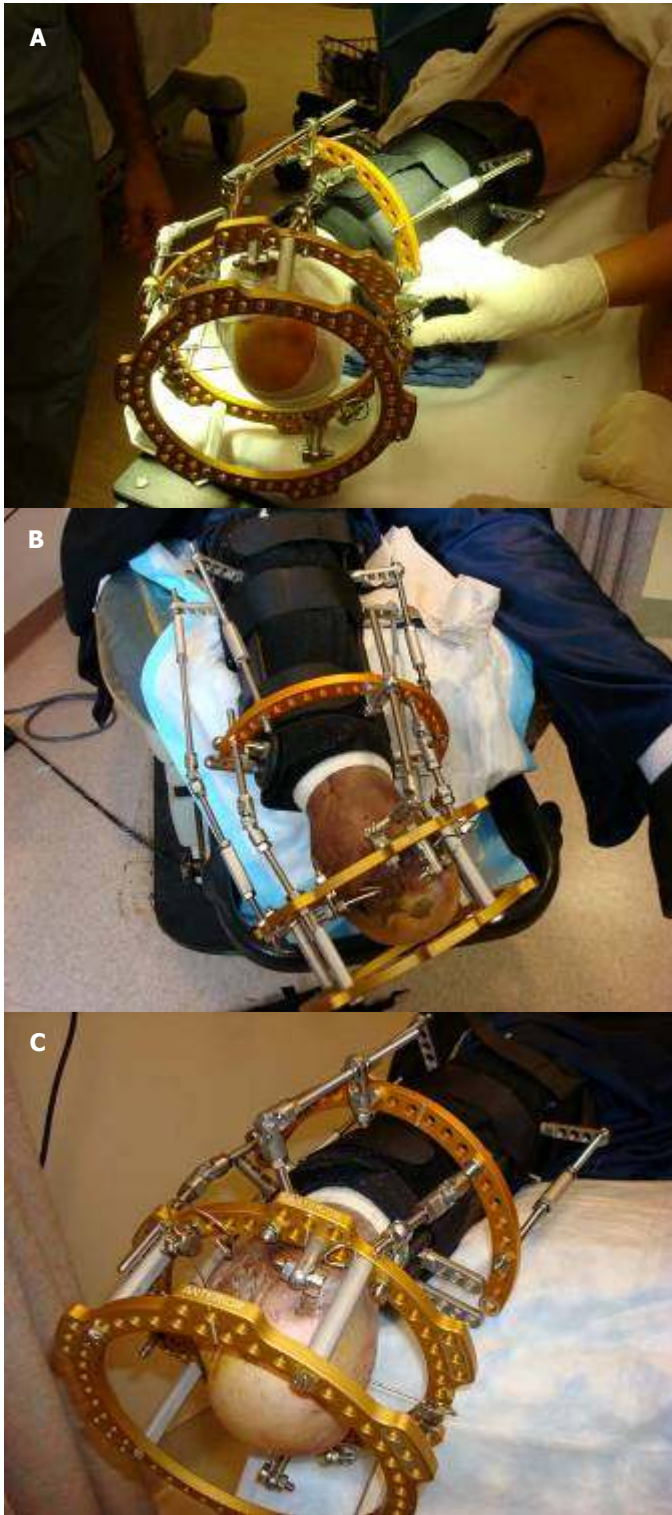
Thereafter, patients are fitted for ankle foot orthoses (AFO) and custom extra depth shoes with appropriate fillers if necessary.

### Case Report 1

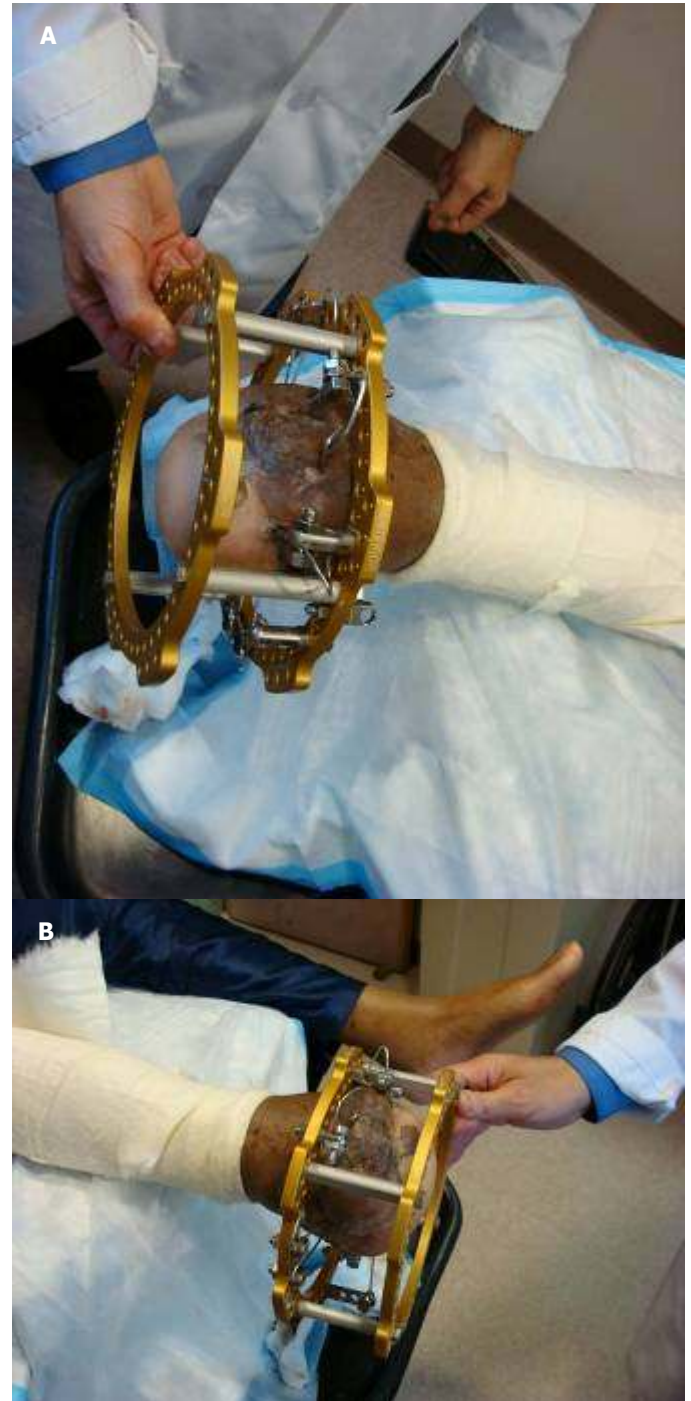This diabetic male patient presented to the Emergency Department with an infected 2<sup>nd</sup> toe leading eventually to a proximal Chopart's Amputation. The patient had multiple debridements and fasciotomies of the leg over a 6 month period. He developed a lateral ankle ulcer and an adducto-varus foot type as a result of muscle imbalances. (Figs. 1A and 1B)

He had the VCAM™ external fixator applied to offload the ulcer and to gradually correct the adducto-varus deformity. The pins were placed distally through the amputation site to create a more stable frame. He had an adjunctive Achilles tenotomy. Weekly adjustments consisted of tightening the lateral aspect of the frame and loosening the medial components to bring the foot perpendicular to the leg. (Figs. 2A, 2B and 2C) After six weeks of weekly adjustments clinical correction of the deformity was achieved and the lateral ulcer healed. The VCAM™ was then removed. (Figs. 3A and 3B) He was then placed in a CROW Walker to weight bear.

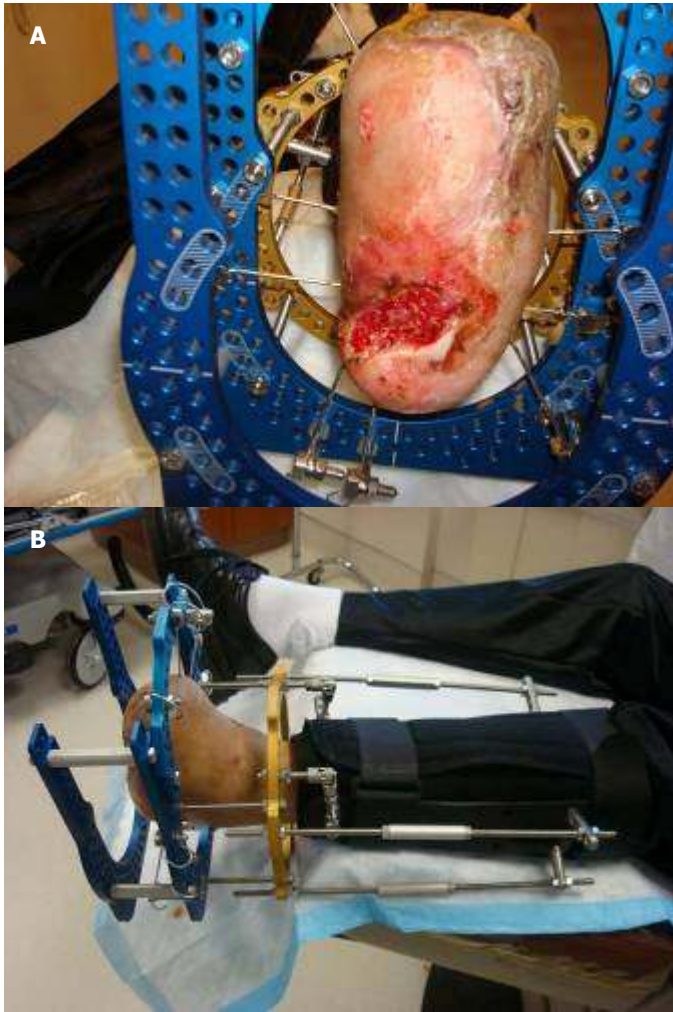Even though the VCAM™ is primarily a below ankle frame it can be designed to imitate a Taylor Spatial™ external fixator, as it was for this case. A half ring was able to be applied above the ankle without any pins inserted into the leg and six struts were fashioned to help achieve gradual triplanar correction of the lower extremity deformity.



**Figure 2A, 2B and 2C** Case 1: Day of VCAM™ application. (A) 1 week after the VCAM™ application with the first adjustment after VCAM™ application. (B) 4 weeks after VCAM™ application with the fourth adjustment. (C)



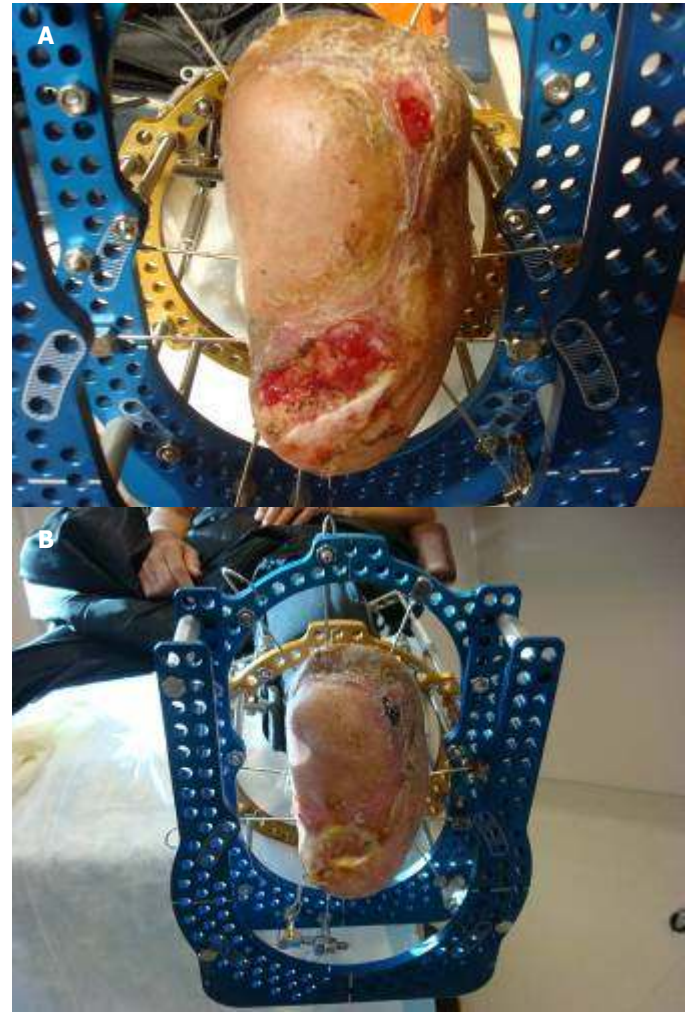
**Figure 3A and 3B** Case 1: 6 weeks after VCAM™ application and there is clinical correction of deformity. The VCAM™ was then removed. (A) The lateral view shows clinical correction of deformity and healed ulceration. (B)



**Figure 4A and 4B** Case 2: Clinical appearance the day of VCAM™ application. (A) The lateral view 1 week after VCAM™ application. (B)

### Case Report 2

A 60 year-old male with history of Diabetes Mellitus with peripheral neuropathy and ESRD, presented to wound care center with a chief complaint of chronic non-healing plantar ulcers of six months duration. The patient had a previous left foot trans-metatarsal amputation (TMA) with an ulcer on the distal plantar lateral aspect of the TMA site and a plantar heel ulcer. Local wound care with weekly debridements failed to heal the ulcers. The plantar heel ulcer measured 5cm x 6cm and probed to bone.



**Figure 5A and 5B** Case 2: 2weeks after VCAM™ application showing ulcer healing with associated pin tract infections. (A) 4 weeks after VCAM™ application with progressive closure of the ulcers.

It was then decided to proceed with surgical debridement of the ulcer and VCAM™ application. On March 3<sup>rd</sup>, 2008 a percutaneous tendo-Achilles lengthening (TAL) and tenotomy of the anterior tibial tendon were performed to relieve forefoot pressure on the distal plantar lateral TMA site ulcer. The Versajet Hydrosurgery System™ (Smith & Nephew) was used to debride the plantar ulcers of all necrotic tissue and then application of Apligraf® (Organogenesis) skin substitute was applied to the heel ulcer. At this point, a VCAM™ external fixator

was applied to offload the plantar ulcerations and help maintain angular correction after TAL and anterior tibialis tenotomy. The pins for the frame were thrown distally through the TMA site exiting posterior to the heel to help create a more stable construct. The VCAM™ in this case is a standard Ilizarov type frame and was primarily used to offload the ulcers. (Fig. 4A and 4B) The ulcers were progressing well and had decreased in size significantly until the patient tripped and fell while ambulating which ultimately led to several pin tract infections. (Figs. 5A and 5B) The causative organism of the pin site infections was MRSA. The patient was started on Zyvox® (Pfizer) and the VCAM™ fixator was removed on April 17, 2008.

The distal plantar ulcer healed before the fixator was removed and all wounds healed with continued off-loading after removal. Pin site infections are the most common complication with external fixators. In this case, patient selection was appropriate. He could ambulate without any significant issues prior to VCAM™ application that would deter a foot and ankle surgeon from applying an external fixator. In our opinion the result of the patient falling was accidental.

### Case Report 3

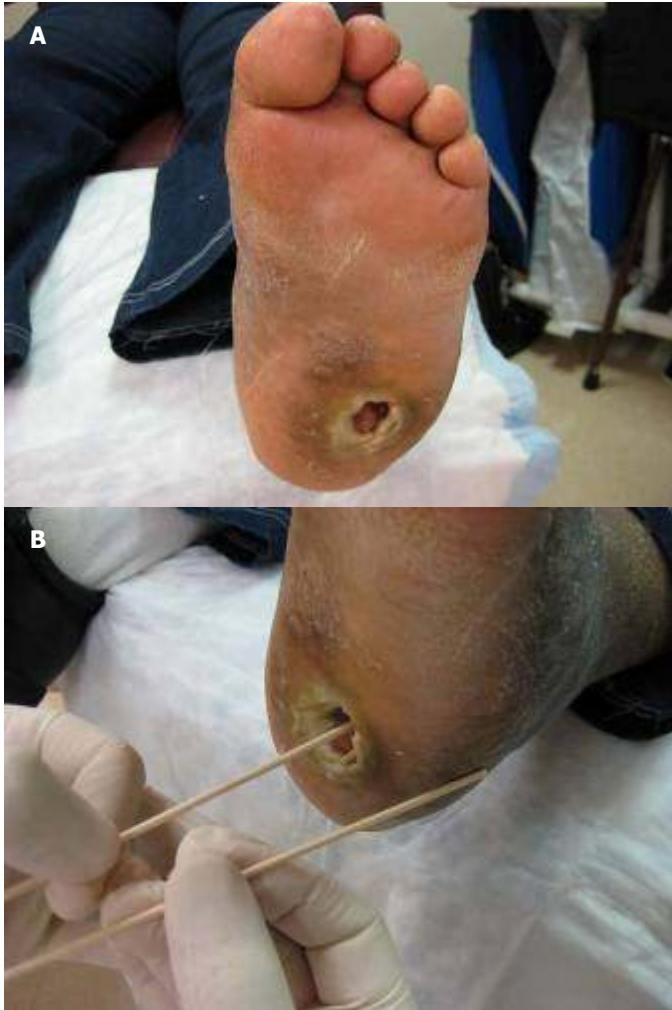
A 51 year-old diabetic female with history of Hypertension, Hypercholesterolemia, Charcot Neuroarthropathy and a non-healing Wagner Grade 3 ulcer measuring 2.4 cm x 2.5 cm x 2.4 cm present for more than 1 year duration, was seen in the Wound Care Center. (Figs. 6A and 6B) Radiographs revealed a Charcot foot deformity with dislocation at the LisFranc and Chopart joints. (Figs. 7A and 7B) After 17 hyperbaric oxygen treatments helped to resolve cyanosis of the digits, it was decided that surgical intervention would be necessary to realign the midfoot and to offload the ulcer.

The patient had a wound debridement, left talar osteotomy, percutaneous Tendo-Achilles lengthening and VCAM™ application. This frame was constructed to offload the ulcer and to compress and realign the midfoot to the hindfoot. One half ring was placed on the dorsal aspect of the foot and another half ring placed posterior to the heel to aid with compression. Realignment of the dislocated joints is evident on the immediate post operative radiographs. The frame was adjusted on a weekly basis. The VCAM™ was successful in producing a more plantigrade foot and offloading the ulcer long enough for it to decrease greatly in size. The frame was removed after 8 weeks and the patient was subsequently put into an ankle foot orthosis. Conservative wound care continued for approximately 2 months until the ulcer healed successfully. (Figs. 8A, 8B and 8C)

### Discussion

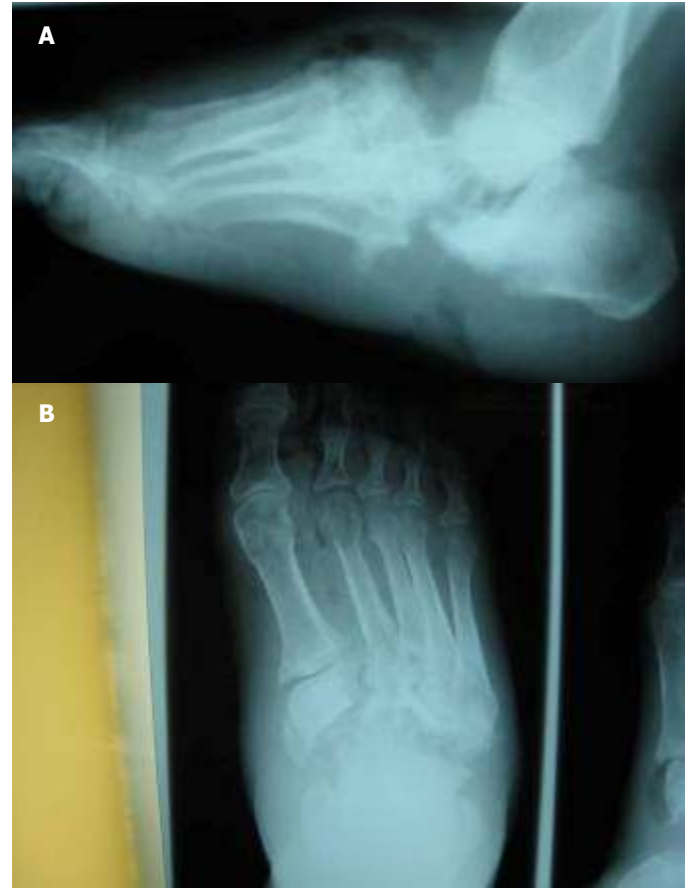External fixators are now almost exclusively used for arthrodesis, management of lower extremity deformities such as Charcot neuroarthropathy, limb lengthening, osteotomy stabilization, osteomyelitis, nonunion or pseudoarthrosis.<sup>1,2</sup> In wound and ulcer management it provides offloading and potentiates healing. It has proven extremely useful in treatment of these conditions because it can provide distraction, compression, stabilization and neutralization as needed.<sup>2</sup>

There is limited mention in the literature of external fixation devices that do not extend proximal to the ankle. Herbst uses two types of external fixation devices for the treatment of Charcot Arthropathy. One is a foot frame and the other a tibio-calcaneal frame. He uses the foot frame for the correction of midfoot deformity. The main characteristics are a hindfoot ring and a forefoot ring in the coronal plane. The two rings have a spanning device between them to provide compression across the midfoot.<sup>7</sup> Malizos, et al., described an Ilizarov below the ankle circular frame to treat displaced calcaneal fractures. There are 2 rings both confined to the foot.



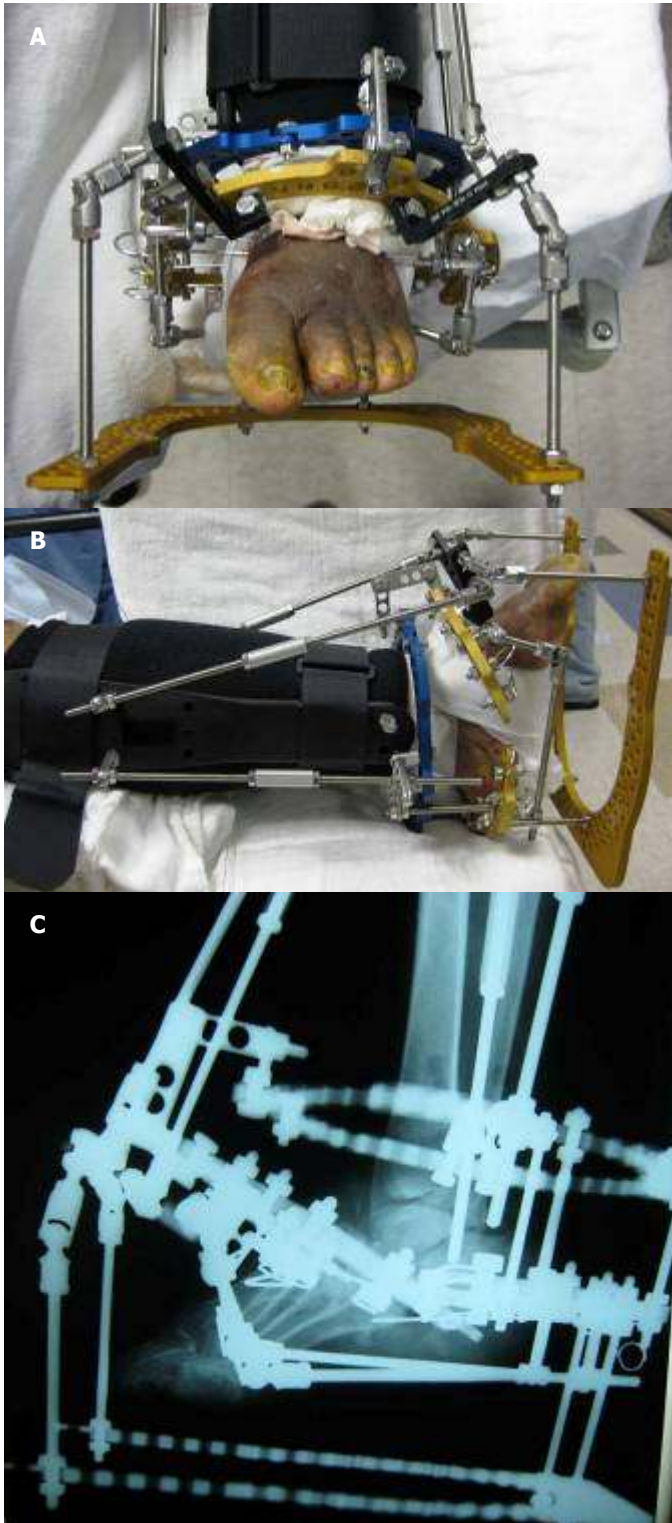
**Figure 6A and 6B** Case 3: The Initial clinical appearance; plantar view of the foot. (A) The Initial clinical appearance demonstrating the depth of the ulcer. (B)

The proximal ring serves a stable ground through the talus and midfoot bones and supports the distal ring. The 2 rings are distracted to withstand the deforming forces of the Achilles tendon, the plantar musculature, aponeurosis and peroneal retinaculum. Ligamentotaxis can be used for reduction of fragments. Reduction of the shape and height of the calcaneus is easy with the use of gradual distraction. They concluded that rings attached to the distal tibia are not necessary.



**Figure 7A and 7B** Case 3: The initial radiographic lateral view. (A) The initial radiographic dorsoplantar view. (B)

Possible complications associated with the external fixator include: uncontrollable edema with drainage exiting at the pin tract sites, pin tract infections, pin loosening, pin irritation, pin/wire breakage, thermal necrosis, non-union, delayed union, malunion, osteomyelitis, joint contractures/subluxation, wound dehiscence, compartment syndrome, reflex sympathetic dystrophy and fracture after frame removal.<sup>2</sup> Many of these complications can be avoided with post-operative compliance and follow-up care. Edema can be alleviated by elevation and partial weight-bearing immediately post-op. Another potential complication is severe pain and damage due to pins or wires compromising muscles, tendons or neurovascular structures.



**Figure 8A, 8B and 8C** Case 3: Day of VCAM™ application. (A) The foot is placed in a more plantarflexory position to promote ulcer closure. (B) The immediate post-op lateral radiograph. (C) The immediate post-op lateral radiograph.

This complication is decreased with the use of the VCAM™, as no pins are passed through the leg. Major complications such as infection and wire breakage alter the postoperative course and often require removal of the external fixator.<sup>9</sup>

In the cases presented it is evident that the VCAM™ can be constructed in many configurations and therefore be used to treat a variety of lower limb deformities that could lead to ulcerations. In the first case the VCAM™ was applied to achieve gradual correction of a triplanar deformity. It was successful in doing so without the use of leg pins or wires. In the second case it was used a traditional Ilizarov frame to simply offload the extremity to assist in healing two plantar ulcers. In the third case it was again constructed as an Ilizarov type frame to offload a plantar ulcer and to provide compression of the midfoot to the hindfoot. In all three of these cases the VCAM™ was successful and proved to be a useful device to heal ulcerations and correct deformities without the use of leg pins or wires. One of the disadvantages of the VCAM™ as seen in the second case was the development of pin tract infections. This is the most common disadvantage with any external fixator, but the absence of leg pins in our opinion decreases the chance of pin tract infections with the VCAM™. More case studies and research should be explored with the VCAM™ in the areas of trauma especially Lisfranc fractures since it is a midfoot deformity and other lower limb deformities.

In conclusion we feel that the VCAM™ is an excellent modality when managing limb deformities that have lead to the development of ulcerations. It provides a means of realigning the foot in all necessary planes while simultaneously offloading ulcerations. The benefits greatly outweigh the risks associated with use of this device. We have seen good results using this device and recommend it for offloading ulcerations secondary to limb deformities. More case studies and research should be explored with the VCAM™ in the areas of trauma especially Lisfranc fractures since it is a midfoot deformity and other lower limb deformities.

## References

1. Hamilton GA, Ford FA. External fixation of the foot and ankle Elective indications and techniques for external fixation in the midfoot. *Clin Podiatr Med Surg* 2003 20:45-63.
2. Baker MJ, Offutt SM. External fixation Indications and patient selection. *Clin Podiatr Med Surg* 2003;20:9-26.
3. Vito GR, Talarico LM, Kanuck DM. Use of external fixation to correct deformities of the lower leg. *Clin Podiatr Med Surg* 2003 20:119-157.
4. Cooper PS. Application of external fixators for management of Charcot deformities of the foot and ankle. *Foot Ankle Clin N Am* 2002 7:207-254.
5. Cooper PS. Application of external fixators for management of Charcot deformities of the foot and ankle. *Semin Vasc Surg* 2003 16: 67-78.
6. Jolly GP, Zgonis T, Polyzois V. External fixation in the Management of Charcot Neuroarthropathy. *Clin Podiatr Med Surg* 2003 20:741-756.
7. Herbst, S. External fixation of Charcot Arthropathy. *Foot Ankle Clin N Am* 2004 9:595-609.
8. Malizos KN, Bargiotas K, Papatheodorou L, Dimitroulias A, Karachalios T. The below-the-ankle circular frame: A new technique for the treatment of displaced calcaneal fractures. *J Foot and Ankle Surg* 2005 45(5):295-299.
9. Bevilacqua NJ, Rogers LC. Surgical management of Charcot midfoot deformities. *Clin Podiatr Med Surg* 2008;25:81-94.